

An Evaluation of The Various Modalities Used for Treatment of Low Fistulas and Their Outcome at a Tertiary Care Center

Article History
Received: 15.02.2022 Revision: 20.03.2022 Accepted: 01.04.2022 Published: 21.04.2022 Plagiarism check - Plagscan DOI: 10.47310/iarjmsr.2022.V03i02.03
Author Details
Dr. Manjunath savanth* ¹ , Dr. Clement R S Dsouza ² , Dr. Reshmina Chandni Clara Dsouza ³ and Dr. Shubha N Rao ²
Authors Affiliations
¹ Department of General Surgery, Father Muller Medical College, Mangalore, India ² Professor, HOD and Unit Chief Department Of General Surgery, Father Muller Medical College, Mangalore, India ³ Associate Professor Department of General Surgery, Father Muller Medical College, Mangalore, India
Corresponding Author*
Dr. Manjunath savanth
How to Cite the Article:
Dr. Manjunath savanth, Dr. Clement R S Dsouza, Dr. Reshmina Chandni Clara Dsouza and Dr. Shubha N Rao (2022); An Evaluation Of The Various Modalities Used For Treatment Of Low Fistulas And Their Outcome At A Tertiary Care Center. <i>IAR J. Med & Surg Res.</i> 3(2) 9-12
Copyright @ 2022: This is an open-access article distributed under the terms of the Creative Commons Attribution license which permits unrestricted use, distribution, and reproduction in any medium for non commercial use (NonCommercial, or CC-BY-NC) provided the original author and source are credited.

Abstract: A fistula-in-ano is an abnormal hollow tract or cavity that is lined with granulation tissue and that connects a primary opening inside the anal canal to a secondary opening in the perianal skin; secondary tracts may be multiple and can extend from the same primary opening. Anal fistula is a common peri-anal surgical problem with which the patient presents the clinician. The study was done at in the department of General Surgery in father muller Medical College Hospital during the period from October 2018 - October 2020. Data was collected from the operated cases of all types of peri-anal fistula above 18 years and below 60 whose follow up was done for at least 6 months. In the study of 50 cases were randomly selected patients of fistula in ano, 84% of them had only one external opening, while 10% had 2 external opening and another 6% had more than 2 openings, hence fistula in ano with a single external opening is commonest in occurrence.

Keywords: Post-Operative Morbidity, Body Mass Index, SPSS, Diabetes.

INTRODUCTION

A fistula-in-ano is an abnormal hollow tract or cavity that is lined with granulation tissue and that connects a primary opening inside the anal canal to a secondary opening in the perianal skin; secondary tracts may be multiple and can extend from the same primary opening (Kumar, V. H. *et al.*, 2015). Anal fistula is a common peri-anal surgical problem with which the patient presents the clinician. Most anal fistulas form a good treatable benign lesion of the rectum and anal canal.

90% or more of these cases are a finale of the infections of the cryptoglandulares (Abcarian, H. 2011).

As such, the vast majority of these infections are acute and significant majority is a contributory to chronic, low-grade infections.

Most of these anal fistulae are easy to diagnose with a good source of light, a proctoscope and digital rectal examination. Despite this establishing a complete cure of these anal fistulae is very problematic for these two reasons. First cause being the affection of the disease with respect to the site. Secondly, the significant percentage of these diseases persists or resumes when the correct type of surgery is not adopted or when postoperative care is insufficient, or intra-operative if the extensions

are lost or unnoticed (Hokkanen, S. R. *et al.*, 2019).

Perianal fistulae is a clinical entity with significant patient morbidity. While multiple surgical options exist, recurrence rates and the risk of fecal incontinence are important considerations in management strategy.

The state of the spectrum requires the importance of finding the most common cause and therefore a better understanding of the targeted and specialized management of the condition. In this paper, an attempt is made to study the presenting symptoms, the various secondary etiologies, the findings on clinical examination, various surgical procedures with their short term outcomes like patient satisfaction, pain of procedure and the short term post-operative complications of various procedures.

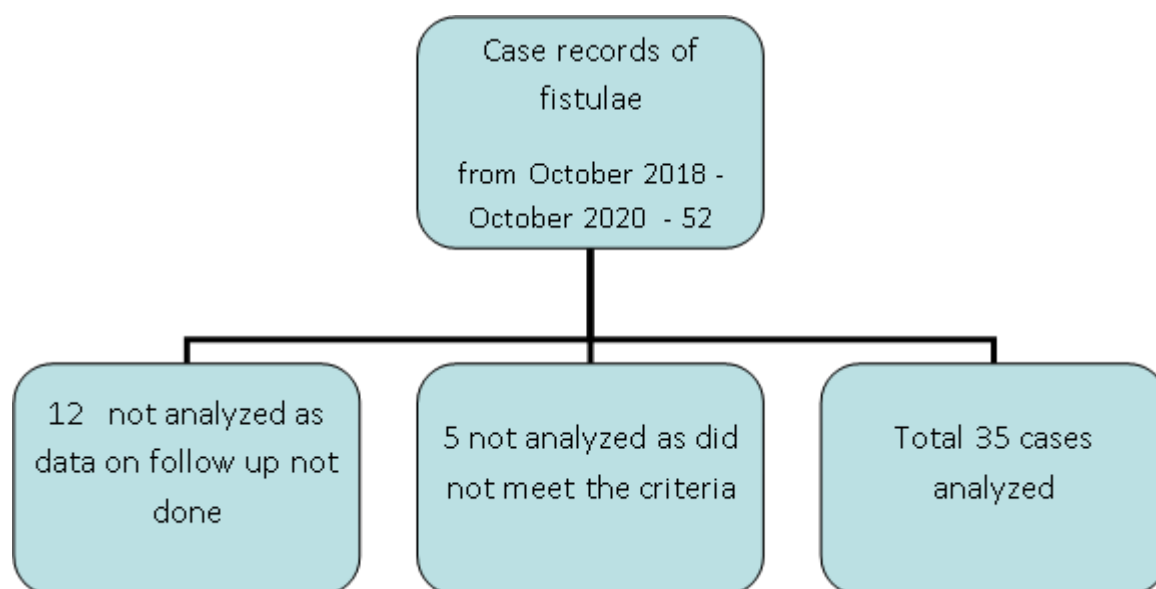
Fistula-in-ano form a good majority of treatable benign lesions of rectum and anal canal. 90% or so of these cases are end results of cryptoglandular infections. It has been said that more surgeons' reputations have been impinged because of the consequences of fistula operations than from any other operative procedure. Complications of fistula surgery are myriad and include faecal soilage, mucous discharge, varying degrees of incontinence (flatus or faecal) and recurrent abscess and fistula (Sainio, P. 1984).

Over the past few years there has been a lot of advances that have occurred in the management of peri anal fistula. Earlier the treatment would be either fistulectomy or fistulotomy, nowadays minimally

invasive surgeries like VATS is being tried with success noted even in the management of high fistulas as a single stage procedure obviating the need for a staged procedure. Also the etiology of fistulas is changed and secondary fistulas are becoming more as compared to the past

MATERIALS AND METHODOLOGY:

The study was done at in the department of General Surgery in Father Muller Medical College Hospital during the period from October 2018 - October 2020. Data was collected from the operated cases of all types of peri-anal fistula above 18 years and below 60 whose follow up was done for at least 6 months.



RESULTS AND OBSERVATIONS

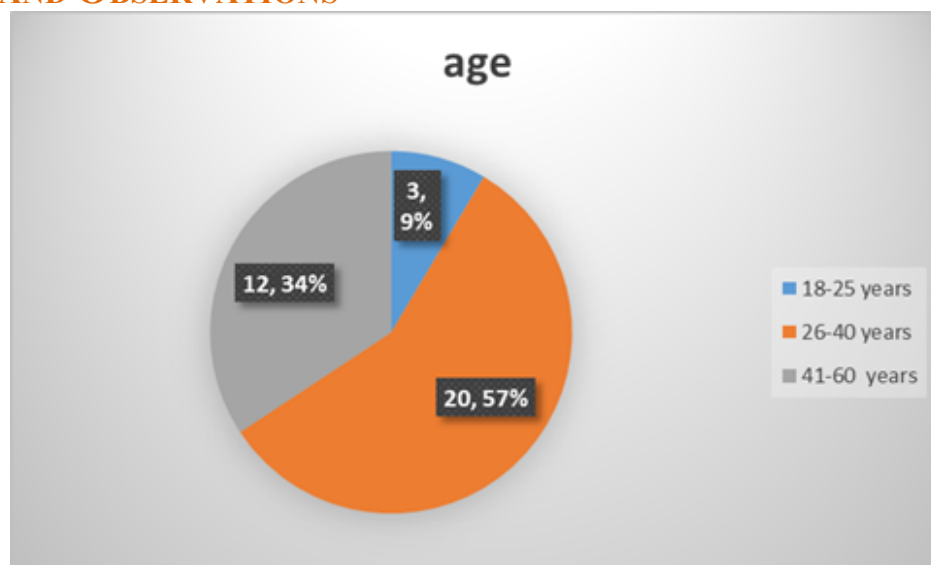


Fig.1

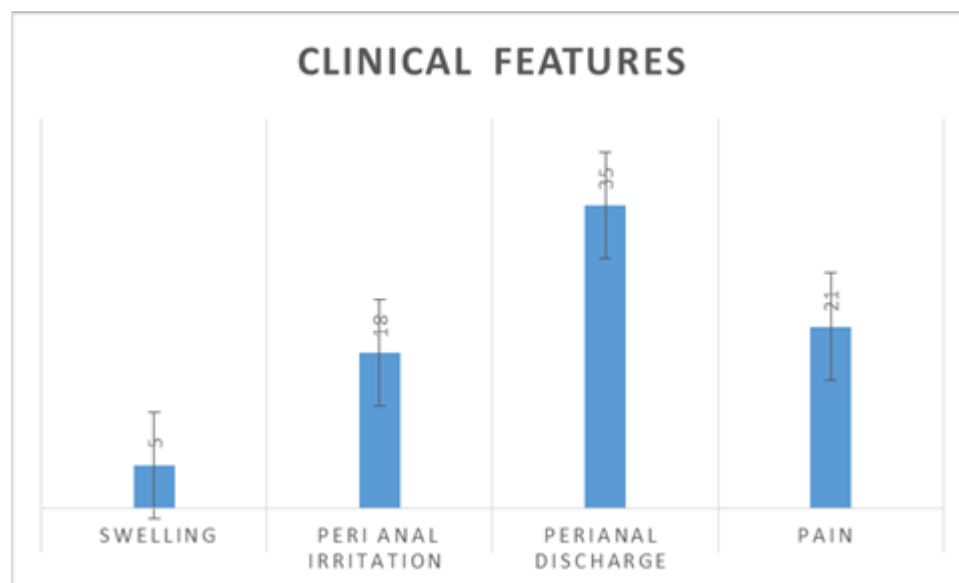


Fig.2

Table.1

GENDER	FEMALES	MALES
percentage	14.29%	85.71%
frequency	5	30

Table.2

	frequency	percentage
Site Of Fistula		
Intersphincteric	23	65.71%
Transsphincteric	12	34.29%
External Opening		
3 oclock	6	17.14%
4 -5oclock	1	2.86%
6 oclock	4	11.43%
7,8 oclock	2	5.71%
9 oclock	1	2.86%
10,11 oclock	15	42.86%
12 oclock	6	17.14%
history of Perianal Abscess		
yes	5	14.29%
no	30	85.71%
Type of Fistula		
Lowanal Fistula	35	100.00%
operation performed – fistulectomy, fistulotomy, LIFT operation		
fistulectomy,	32	91.43%
fistulotomy	3	8.57%
recurrence at 8 months		
yes	1	2.86%
no	34	97.14%

DISCUSSION

Parks, A.G. *et al.*, (1976) in British Journal of Surgery classified the Fistula In Ano into four types based on level of the fistula with respect to the sphincter.

Appropriate classification is essential for adequate treatment and conservation of the external anal sphincter to preserve fecal continence.

- Intersphincteric (45%) – The fistula penetrates through the internal sphincter but spares the external sphincter.
- Transsphincteric (30%) – The fistula passes through both the internal and external sphincters.
- Suprasphincteric (20%) – The fistula penetrates through the internal sphincter and then extends superiorly in the plane between the sphincters to pass above the external sphincter before extending to the perineum. This classification includes horseshoe abscesses.
- Extrasphincteric (5%) – This fistula is very rare. It forms a connection from the rectum to the perineum that extends laterally to the internal and external sphincter. These can be the most difficult to treat due to the need to preserve the sphincter complex.

Irfan Parvez Quresh *et al.*, (2018) in n Index Medical College Hospital, Indore during the study period January 1, 2015 to December 31, 2017 a Total 44 cases of fistula in ano were selected randomly using closed envelope method and studied in detail the following results were obtained. In this present series, 56.81% of patients were in the age group of 31-60 years followed by 34.09% of patients were in the age group of 11-30 years. Only 9.09% of patients were in the age group above 60 years. About major clinical features were noted perianal

discharge, pain, swelling and peri anal irritation were 75%, 65.91%, 43.18% and 11.36% respectively. They stated that early diagnosis and appropriate management is the key to success. Fistula-in-ano forms a good majority of treatable benign lesions of rectum and anal canal. 90% or so of these cases are end results of cryptoglandular infections.

Yadu, S., & Toppo, A. (2018) in a cross sectional observational prospective study was conducted in 50 patients who presented with Fistula-in-ano to Dr. B.R.A.M. Hospital, Raipur found that % patients are in the age group of 41-50. 82% are male patients and 18% patients are female patient. 76% Patients had single opening. 74% Patients had perianal discharge while 66% patients presented with perianal pain. 40% patients had h/o perianal abscess. Most common mode of presentation was discharge. 76% patients had posterior opening while 24% patients had anterior opening. Fistulectomy and fistulotomy were performed in 39 subjects (78%) and 7 subjects (14 %) respectively. and they concluded that Anal fistula is a common disease which is devastating to the patients and imposes challenges to the surgeon. Early diagnosis and appropriate management are the key to success.

Sukhlecha, A. G. (2019) in An Evaluation of the Clinical Presentation and The Management Modalities Of Perianal fistula done at medical institute for the period of 1 year. 50 cases, found 44% of patients were in the age group of 31-40 years. 70% of patients were, discharging wound was the presenting the complaint. 20% of patients with pain and swelling around the anal region. In the study of 50 cases were randomly selected patients of fistula in ano, 84% of them had only one external

opening, while 10% had 2 external opening and another 6% had more than 2 openings, hence fistula in ano with a single external opening is commonest in occurrence.

REFERENCE

1. Abcarian, H. (2011). Anorectal infection: abscess–fistula. *Clinics in colon and rectal surgery*, 24(1), 14–21.
2. Hokkanen, S. R., Boxall, N., Khalid, J. M., Bennett, D., & Patel, H. (2019). Prevalence of anal fistula in the United Kingdom. *World journal of clinical cases*, 7(14), 1795–1804.
3. Kumar, V. H., Chetan, P. R., & Naveen, P. R. (2015). A clinico-pathological study of fistula-in-ano. *Sch J App Med Sci*, 3(3F), 1471-1476.
4. Parks, A.G., Gordon, P.H., & Hardcastle, J.D. (1976). A Classification of Fistula in Ano. *British Journal of Surgery* 63, 5.
5. Qureshi, I. P., Sahani, I. S., Qureshi, S., & Modi, V. (2018). Clinical study of fistula in ano in patients attending surgical OPDs of a tertiary care teaching hospital, Central India. *International Surgery Journal*, 5(11), 3680-3684.
6. Sainio, P. (1984). Fistula-in-ano in a defined population. Incidence and epidemiological aspects. *Ann Chir Gynaecol*. 73, 219–224.
7. Sukhlecha, A. G. (2019). Prevalence of fistula-in-ano in patients attending tertiary care institute of Gujarat: a cross-sectional study. *International Surgery Journal*, 6(7), 2449-2452.
8. Yadu, S., & Toppo, A. (2018). Clinical presentation and outcome of fistula in ano cases. *International Surgery Journal*, 5(9), 3006-3010.