

## Effect of Laser Bio stimulation and Bone Graft in Treatment of a Large Periapical Lesion – A CBCT Analysis

Article History
<b>Received: 15.01.2022</b> <b>Accepted: 29.01.2022</b> <b>Revision: 08.02.2022</b> <b>Published: 19.02.2022</b> <b>Plagiarism check - Plagscan</b> <b>DOI: 10.47310/iarjmsr.2022.V03i01.04</b>
Author Details
Dr. Ruchika Gupta Dewan <sup>1</sup> and Dr. Unnavi Chauhan <sup>2</sup>
Authors Affiliations
<sup>1</sup> Professor, Department Of Conservative Dentistry and Endodontics, ITS Dental College, Hospital and Research Centre, Greater Noida, Uttar Pradesh, India  <sup>2</sup> Intern, ITS Dental College, Hospital and Research Centre, Greater Noida, Uttar Pradesh, India
Corresponding Author*
<b>Dr. Ruchika Gupta Dewan</b>
How to Cite the Article:
Dr. Ruchika Gupta Dewan and Dr. Unnavi Chauhan (2022); Effect of Laser Bio stimulation and Bone Graft in Treatment of a Large Periapical Lesion – A CBCT Analysis. <i>IAR J. Med &amp; Surg Res.</i> 3(1) 15-18.
<b>Copyright @ 2022:</b> This is an open-access article distributed under the terms of the Creative Commons Attribution license which permits unrestricted use, distribution, and reproduction in any medium for non commercial use (NonCommercial, or CC-BY-NC) provided the original author and source are credited.

**Abstract:** Nonsurgical endodontic treatment is a definitive predictable treatment option in most cases, but endodontic surgery may be indicated for teeth with persistent peri apical pathosis unresponsive to non-surgical approaches. This paper reports the one case of bone healing after peri apical surgery using laser biostimulation and hydroxyapatite bone graft assessed using CBCT analysis. Each case was evaluated using Pre-operative CBCT. Post treatment evaluation was done clinically, radiographically and by CBCT analysis.

**Keywords:** Periapical Lesion, Laser Biostimulation, Bone graft, CBCT.

### INTRODUCTION

Apical surgery is the surgical management of a tooth with a periradicular or periapical lesion that cannot be resolved with an orthograde endodontic treatment. Apical surgery is often considered as a last resort to preserve a tooth when conventional endodontic retreatment is not feasible or is associated with therapeutic risks (Kim and Kratchman, 2006). The treatment alternative for surgery would be tooth extraction, or in multi-rooted teeth, root or tooth resection (von Arx, T., & AlSaeed, M. 2011).

When periapical surgery is indicated, diseased soft tissue is removed and application of different graft material enhances new bone formation at the defective site. Formation of new bone can occur with regeneration or repair. The most commonly used technique for regeneration is the use of bone replacement grafts. The ideal bone replacement material should be easy maneuverable, inert, noncarcinogenic, and should be dimensionally stable. One of the promising biomaterials for bone healing and regeneration is Biphasic calcium phosphate ceramic.

The goal of surgical endodontic treatment is to eradicate any associated extraradicular infection such as periapical granulomas and cysts (Monga, P. *et al.*, 2016). Low intensity laser Therapy accelerates the repair process and has bio-stimulating effects on stem cells of bone

(Ebrahimi, T. *et al.*, 2012). Application of Laser is painless, non invasive and without adverse effects (Obradovic, R. *et al.*, 2007). Recently, cone beam computed tomography (CBCT) has been introduced as it eliminates some of the most prevalent problems, such as superimposition and distortion and is a method of gaining an unabridged view of dental anatomy. CBCT is rapidly replacing other radiographic techniques in diagnosis, quality control of treatment methods and techniques, and outcome assessment and reduces false diagnosis (Peters, C. I., & Peters, O. A. 2012). In this case report Periapical surgery was conducted followed by Laser Biostimulation and placement of Hydroxyapatite bone graft.

### CASE REPORT

A 35 year old male patient reported to the Department with the chief complaint of discolored tooth in the upper front tooth region since 4-5yrs. The patient had reported trauma in the same region 7 years back. Patient revealed history of RCT irt 11. The past medical history of the patient did not reveal any significant finding and the patient was systemically healthy and was not on any medication. Patient revealed no history of alcohol, smoking and other deleterious habits. On examination, the tooth appeared was discolored with pain on palpation irt 11,12 and with Ellis class IV fracture in relation to 12.

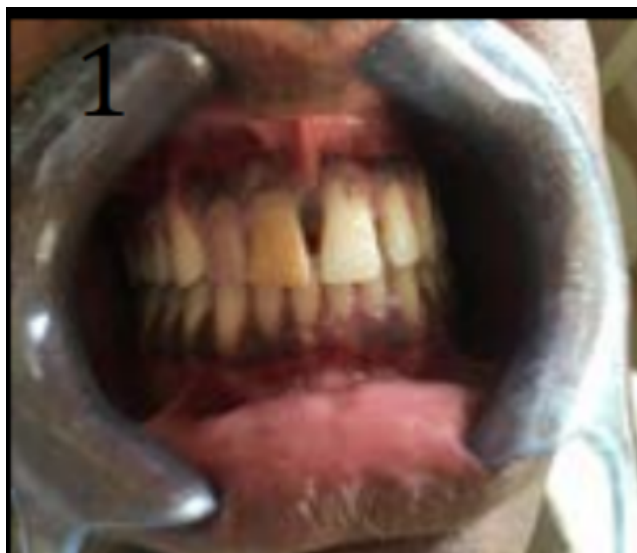

Figure-1: Pre-operative Clinical picture

The pulp vitality tests irt 12 revealed that the tooth was nonvital while the radiographic examination of the concerned area in the form of an intra-oral peri-apical radiograph (IOPAR) revealed that it had a large peri-apical radiolucency.

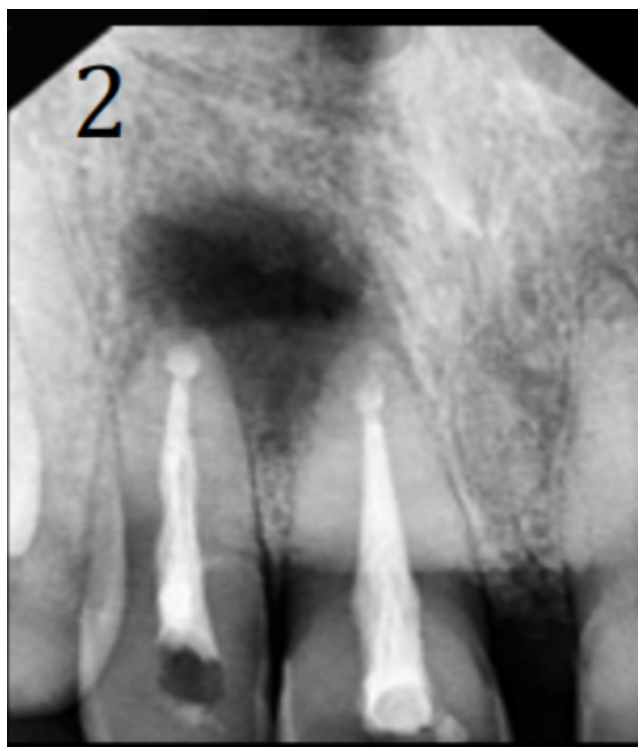
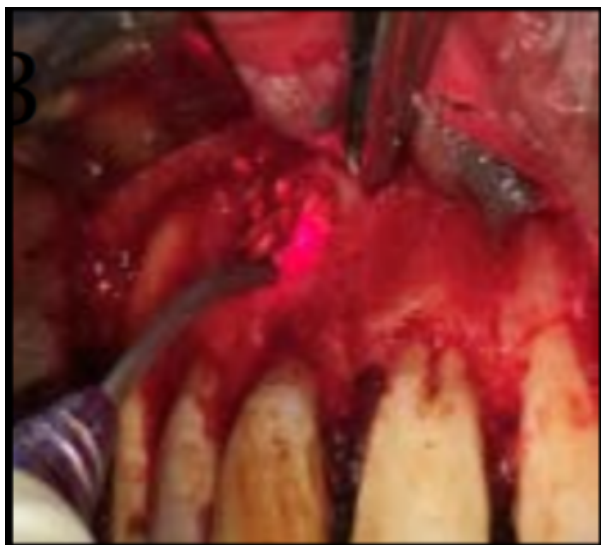
Figure: 2 Preoperative Radiographs

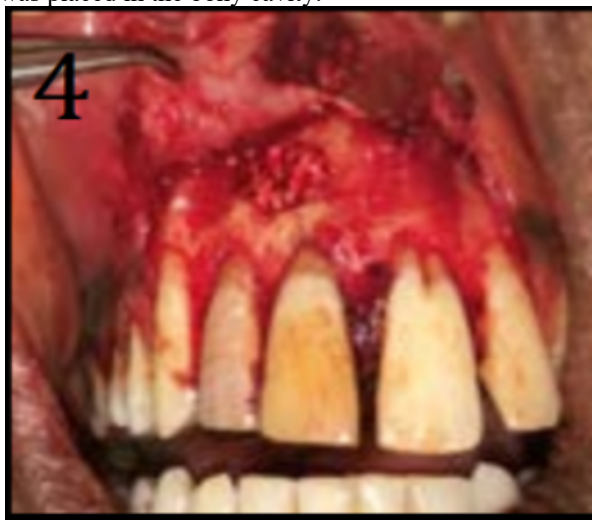Peri-apical surgery was thus planned considering the size of the lesion. Blood hemogram tests were conducted prior to surgery. On the day of surgery patient was administered local anesthesia. Full thickness mucoperiosteal flap was reflected by giving two vertical incisions and a horizontal incision. Osteotomy was performed under copious water spray using straight micromotor handpiece with bone cutting bur. Root was resected up to 3mm. Removal of granulation tissue was done using curettes. Retrograde cavity preparation was done using micromotor contra angle handpiece and round bur.

Retrograde Root filling was done using MTA at root end with the help of MAP system. After MTA placement, Laser Biostimulation with soft tissue diode Laser in non contact mode was used in elliptical manner. Three cycles of laser biostimulation were done of 10 seconds each. The power in first cycle was 1.5 watt with 3 cm away from the lesion site. In second cycle the power was increased to 2 watt with decrease in the distance to 2cm and third cycle was performed with maximum power up 2.5watt and minimum distance of 1 cm. Each cycle had interval of 10 seconds which was the rest phase.

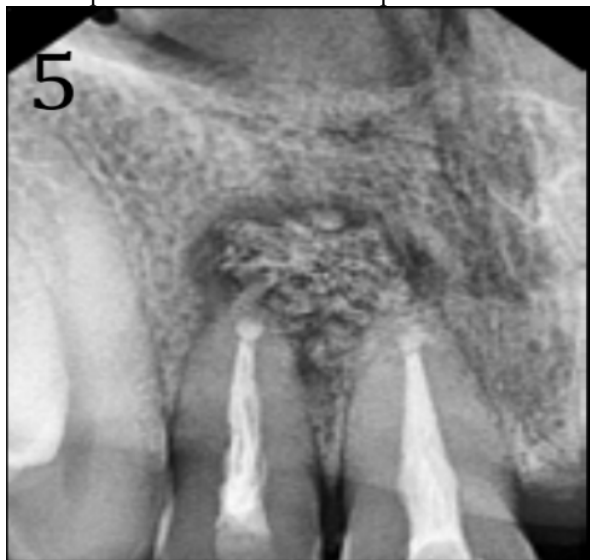

**Figure:3** Laser Biostimulation

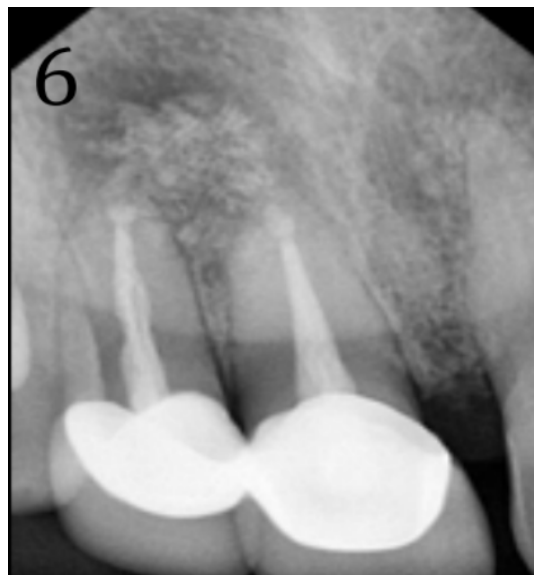
After Laser Biostimulation, Hydroxyapatite bone graft was placed in the bony cavity.



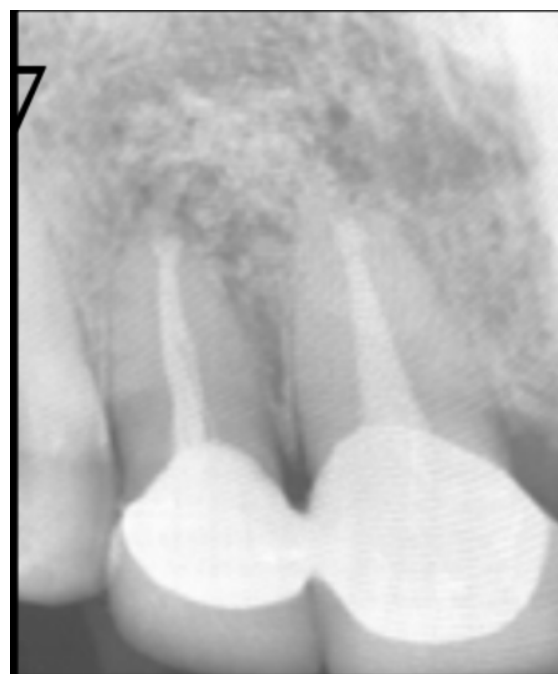**Figure: 4** Placement of Bone Graft in the Bony socket  
The Flap was then sutured back in position.



**Figure 5:** 1 month follow up Radiograph



**Figure 6:** 6 months follow up Radiograph



**Figure 7:** 1 year follow up Radiograph

**CBCT** Scan was taken immediately after the surgery for the measurement of the bone defect

**CBCT I.** Mesio-distally, superioinferiorly and labiopalatally the defect measured 9.4 mm, 11 mm, 7.4 mm respectively.

**CBCT II** was taken after 1 year which revealed reduction in the size of the defect up to mesio-distally, superioinferiorly and labiopalatally as 9.2 mm, 7.9 mm, 5.1 mm. respectively.

The patient was recalled after a period of 1 month, 6 months, and 1 year for radiographic and clinical evaluation (Rud *et al.*, Criteria). Radiographs also revealed a considerable healing of the periapical bone defect.

## DISCUSSION

Nonsurgical endodontic treatment is a highly predictable treatment option in most cases, but endodontic surgery may be indicated for teeth with persistent periradicular pathosis unresponsive to non-surgical approaches. Surgical root canal therapy including root-end resection has been practiced since at least the mid 1800s. When indicated, periapical surgery involves removal of diseased soft tissue, root resection followed by retrograde root filling and application of different graft material, which enhance new bone formation at site of defect.

In the present case Mineral Trioxide Aggregate (MTA) was used as a root-end filling material. It is less cytotoxic than amalgam, IRM, amalgam, or SuperEBA and has an antimicrobial effect. It is shown to promote osteoblastic activity and have excellent sealing ability. Results of MTA studies in dogs and monkeys showed that significantly less inflammation was seen with MTA than with amalgam. More importantly, cementum bridges formed directly over the MTA confirming the tissue friendliness of the material and its potential cementogenic property as root-end filling material (Baek, S. H. *et al.*, 2010).

In present case Laser biostimulation was done followed by placement of hydroxyapatite bone graft. Hydroxyapatite is a cheap and easily available bone substitute. Hydroxyapatite is an apatite of calcium phosphate,  $\text{Ca}_{10}(\text{PO}_4)_6(\text{OH})_2$ , a ceramic naturally found in tooth, vertebrae and bone. The compound has a Ca/P mole ratio of 1.67, and is formed by precipitation of calcium nitrate and ammonium dihydrogen phosphate. Each pore is 100-140  $\mu\text{m}$  with constant interporous distance (Agarwala, S., & Bhagwat, A. 2005). The use of ceramics based hydroxyapatite Bone graft, which is osteointegrative and osteoconductive; and in some cases, osteoinductive (Kumar, P. *et al.*, 2013). Hydroxyapatite is used in a process wherein the bone is formed by osteoprogenitor cells from the recipient bed into, around, and through a graft and the in-growth of capillaries.

These Hydroxyapatite crystals when used acts as a scaffold upon which new bone is deposited, which is then followed by a slow resorption of the graft. The ceramic materials are sufficiently adaptable to lend themselves to the management of defect pattern encountered in the individual patient. The bone grafts containing hydroxyapatite gets more rapidly incorporated into the host bone, because of presence of biological apatite in its surface. This is one of the rationale for employing bovine bone as a graft material (Kandaswamy, D. *et al.*, 2000). Kenney *et al.*, (1985) in their study used porous hydroxyapatite on periodontal defect and found bone formation from the 3rd month onwards and connective tissue infiltration through the pores.

The follow up examination for the above mentioned case was done after a time interval of 1 month, 6 months and 12 months and periapical healing was observed which was verified both radiographically and by CBCT Analysis. On comparing the preoperative CBCT report with the 1 year follow up of the same; it was observed that there was a good periapical healing.

It was thus concluded that endodontic surgery followed by laser bio stimulation and Placement of Hydroxyapatite bone graft showed promising results for periapical healing.

## REFERENCES

1. Agarwala, S., & Bhagwat, A. (2005). Hydroxyapatite as a bone graft substitute: Use in cortical and cancellous bone. *Indian Journal of Orthopaedics*, 39(4), 254.
2. Baek, S. H., Lee, W. C., Setzer, F. C., & Kim, S. (2010). Periapical bone regeneration after endodontic microsurgery with three different root-end filling materials: amalgam, SuperEBA, and mineral trioxide aggregate. *Journal of endodontics*, 36(8), 1323-1325.
3. Ebrahimi, T., Moslemi, N., Rokn, A. R., Heidari, M., Nokhbatolfighahaie, H., & Fekrazad, R. (2012). The influence of low-intensity laser therapy on bone healing. *Journal of Dentistry (Tehran, Iran)*, 9(4), 238.
4. Kandaswamy, D., Ramachandran, G., Maheshwari, S., & Mohan, B. (2000). Bone regeneration using hydroxyapatite crystals for periapical lesions. *Endodontology*, 12, 51-54.
5. Kenney, E.B., Lakovic, V., Carrenza, F.A. Jr., & Dimitrijenci, B. (1985). The use of porous hydroxyapatite implants in periodontal defects: clinical results after 6 months. *J Periodontol* 56, 42-88.
6. Kumar, P., Vinitha, B., & Fathima, G. (2013). Bone grafts in dentistry. *Journal of pharmacy & bioallied sciences*, 5(Suppl 1), S125.
7. Monga, P., Grover, R., Mahajan, P., Keshav, V., Singh, N., & Singh, G. (2016). A comparative clinical study to evaluate the healing of large periapical lesions using platelet-rich fibrin and hydroxyapatite. *Endodontology*, 28(1), 27.
8. Obradovic, R., Kesic, L., Mihailovic, D., Ignjatovic, N., & Uskokovic, D. (2007). Comparative Efficacy Analysis of Biomaterials and Soft Lasers in Repair of Bone Defects. *Journal of Oral Laser Applications*, 7(3), 161-166.
9. Peters, C. I., & Peters, O. A. (2012). Cone beam computed tomography and other imaging techniques in the determination of periapical healing. *Endodontic topics*, 26(1), 57-75.
10. von Arx, T., & AlSaeed, M. (2011). The use of regenerative techniques in apical surgery: A literature review. *The Saudi Dental Journal*, 23(3), 113-127.