



Ovarian Pathologies in Paediatric Age Group - Our Experience and Review of Literature

Article History
<p>Received: 20.04.2021 Revision: 30.04.2021 Accepted: 10.05.2021 Published: 20.05.2021 Plagiarism check - Plagscan DOI: 10.47310/iajmsr.2021.V02i03.05</p>
Author Details
<p>Dr. Jyotsna Kulkarni¹, Dr. Mandar Vaidya², Dr. Anita Gangurde³, Dr. Satish Kapadnis⁴ & Dr. Rajendra Chaudhari⁵</p>
Authors Affiliations
<p>¹Assistant Professor, Department of General Surgery, Dr. Vasantrao Pawar Medical College, Nashik 3</p> <p>²Associate Professor, Department of General Surgery, Dr. Vasantrao Pawar Medical college, Nashik 3</p> <p>³Assistant Professor, Department of General Surgery, Dr. Vasantrao Pawar Medical College, Nashik 3</p> <p>⁴Rainbow Mother and Child Care Hospital, Mumbai Naka, Nashik 2</p> <p>⁵Associate Professor, Department of Pathology, Dr. Vasantrao Pawar Medical College, Nashik 3</p>
Corresponding Author*
<p>Dr. Jyotsna Kulkarni</p>
How to Cite the Article:
<p>Jyotsna Kulkarni, <i>et al</i>; (2021). Ovarian Pathologies in Paediatric Age Group - Our Experience and Review of Literature. <i>IAJ Med & Surg Res</i>, 2(3), 20-26</p>
Copyright @ 2021:
<p>This is an open-access article distributed under the terms of the Creative Commons Attribution license which permits unrestricted use, distribution, and reproduction in any medium for non commercial use (NonCommercial, or CC-BY-NC) provided the original author and source are credited.</p>

Abstract: Ovarian pathologies presenting as Adnexal Masses are rare in paediatric age group. We present retrospective, multicentric study of 20 cases, managed between Aug 2015 to Aug 2020. Patients' age at the time of presentation ranged from 1 day to 12 years of age, 75% patients falling between 5 to 12 years. 50% patients had Simple follicular cysts, 30% had Dermoid cysts. Ovarian Torsion, Malignancy and Para ovarian cysts comprised the rest of the pathologies. As many as 70% patients presented with acute abdomen due to torsion and the remaining 30% came in elective settings. All patients with acute abdomen underwent emergency laparotomy. Laparoscopy could be offered only to those patients who came in elective settings. Incidence of ovarian pathologies presenting as adnexal masses or with acute abdomen due to compromised blood supply is on the rise. Therefore, adnexal pathologies should be considered in Differential Diagnosis of acute abdomen in paediatric patients. Aggressive surgical intervention at presentation prevents loss of ovary. Extra efforts from the treating physician are required to emphasise the need for long term follow up.

Keywords: Adnexal masses, Ovarian cysts, Torsion, Benign, Malignant.

INTRODUCTION

Ovarian pathologies, although rare in children seem to be on the rise due to rampant use of Hormonal Therapy in prospective mothers.

Majority of the patients present as acute abdomen owing to torsion; oophorectomy is a frequent outcome.

This retrospective study reviews a correlation between underlying pathologies with their surgical outcome and ovarian salvage, in a Tier 2 city in India.

PATIENTS AND METHODS

The records of 20 patients under the age of 12 years, diagnosed with ovarian pathologies, between August 2015 to August 2020, were traced. These patients were treated in three different hospitals in a single, tier 2 city in India. The case data was reviewed and retrospectively analysed based on their age at the time of presentation, presenting complaints, clinical and radiologic findings, management and follow up. After evaluating patients in the OPD, those showing symptoms and signs of acute abdomen, were admitted and investigated after resuscitation. Others were investigated as outpatients and then admitted for elective surgery.

Routine blood investigations were carried out and all patients underwent abdominal Ultrasound (USG) examination.

Colour Doppler was asked for in cases presenting with acute abdomen. CT scans were done wherever required.

Injectable Broad-spectrum antibiotics were administered to all patients.

16 patients underwent Laparotomy by standard lower abdominal incision under General Anaesthesia. Two patients underwent Laparoscopy. Two neonates were managed conservatively.

All operated specimens were sent for Histopathological evaluation.

Average follow-up duration in this study was around one year.

OBSERVATIONS

Oophorectomy was done in 12 patients. Patients' age at the time of presentation ranged from 1 day to 12 years.

Maximum number of patients (15 out of 20) were in between 5 to 12 years of age. Here (**Table 1**) All were premenarchal.

Distribution of cases as per their final diagnosis was as follows: Here (**Table 2**)

14 patients came with acute abdominal presentation of pain and vomiting along with tachycardia and guarding in lower abdomen. In all these cases USGs with Colour Doppler showed Whirlpool sign, suggestive of torsion and compromised blood supply. Out of these 14 patients, 6 patients had Simple follicular cysts (**Fig1: a**); 5 patients showed Dermoid cysts (**Fig 1: c, d**); 2 patients had Ovarian Torsion without any underlying cyst and one patient had torsion of Para ovarian cyst.

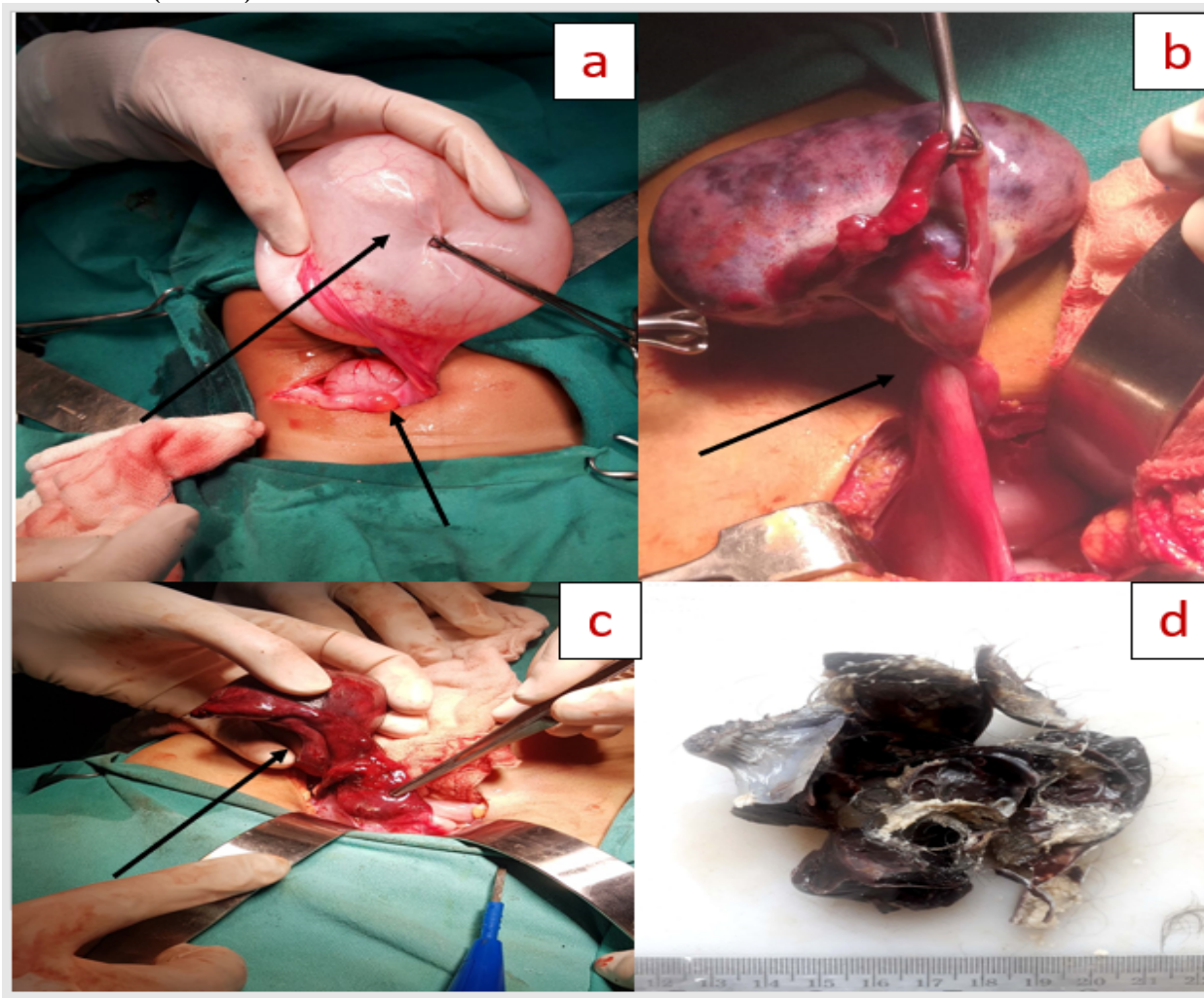


Fig 1: a): Simple Follicular Cyst (Long arrow), Other ovary showing cystic changes (short arrow)

b): Ovarian torsion

c): Dermoid cyst with torsion

d): Cut opened Dermoid cyst, with tuft of hair

There was one patient with more than 10cm diameter simple cyst in the right ovary that had undergone torsion. She also had few smaller cysts in the left ovary. After marsupialisation of this large cyst, some ovarian tissue on the affected side could be preserved. Smaller cysts in the left ovary were punctured.

In one patient with torsion of para ovarian cyst, the ovary was normal. Marsupialisation of the cyst was performed. (**Fig3:a&b**)

The case of a 12-year old girl with hypothyroidism was very unfortunate. This patient was diagnosed to be Hypothyroid based on delayed milestones and lab reports and was put on Thyroid hormone replacement therapy. She had multiple cysts in both ovaries. She

came to us in 2015 with torsion of right ovary which was gangrenous and oophorectomy had to be done. She presented again in 2020 for delayed menarche. It was found that her parents had discontinued thyroid replacement therapy in the interim period, and she had developed torsion in the other ovary for which she underwent oophorectomy in some other city.

We had two patients with Ovarian Torsion without any underlying cyst in the ovary.

One patient gave history of severe lower abdominal pain which had subsided and the abdomen was soft on examination at presentation. She underwent laparoscopy and there was evidence of torsion in the form of haematomas in the broad ligament.

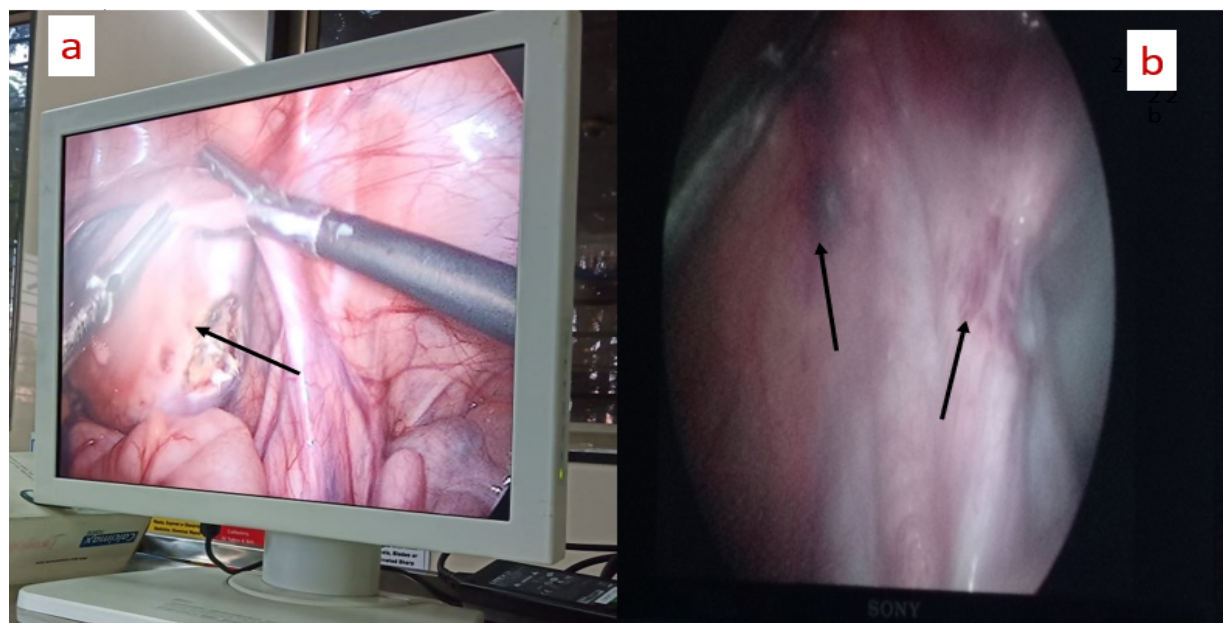


Fig 2: Laparoscopic Images: a): Dermoid cyst excision
b): Hematomas in the broad ligament in a case of ovarian torsion (arrows)

(Fig 2: b) Ipsilateral ovary was viable. Both ovaries were fixed to the lateral pelvic wall.

Other patient presented with acute abdomen and investigations pointed towards ovarian torsion. She had gangrenous ovary on laparotomy which had to be removed. (Fig1:b) Histology did not show any cyst within the ovary.

We had 4 neonates with antenatally detected Simple follicular cysts.

Of these, two neonates had cysts less than 5cm in size that were conserved and were followed up by serial USGs. Spontaneous resolution was seen by 6 and 8 months of age.

One neonate with a simple cyst, around 5 cm in size, was conserved initially, but came back with acute abdomen on D28 of life. She was found to have torsion and oophorectomy had to be done.

One neonate with a simple cyst, less than 5cm to begin with, was conserved initially but on serial USGs, the size was found to be increasing. At 3 months of age, she underwent Laparotomy. Oophorectomy had to be

done as the cyst had replaced the entire ovary. (Fig 1: a)

In all these 4 neonates there was a history of Hormonal Therapy in the mothers, for infertility in 3 and long-term oral contraceptives in one. These patients also showed cystic changes in the other ovary (Fig 1: a) which were monitored and were found to have regressed spontaneously at one year follow up USG.

One 5year old girl presented with Lump in lower abdomen. On investigations, she was diagnosed to have a Dermoid cyst which was removed Laparoscopically. (Fig 2: a)

One patient with huge abdominal lump showed Complex Mass with solid as well as cystic areas, arising from left ovary on CT scan. Her preoperative AFP level was 11ac IU; Beta HCG and CA-125 were normal. After Salpingo oophorectomy, the mass was reported to be Yolk Sac Tumour. She received chemotherapy as per paediatric BEC protocol of Bleomycin, Etoposide and Cisplatin. After surgery and chemotherapy, her serial AFP levels had dropped to 1000 IU; after which she was lost to follow up. (Fig 4: a, b, c).

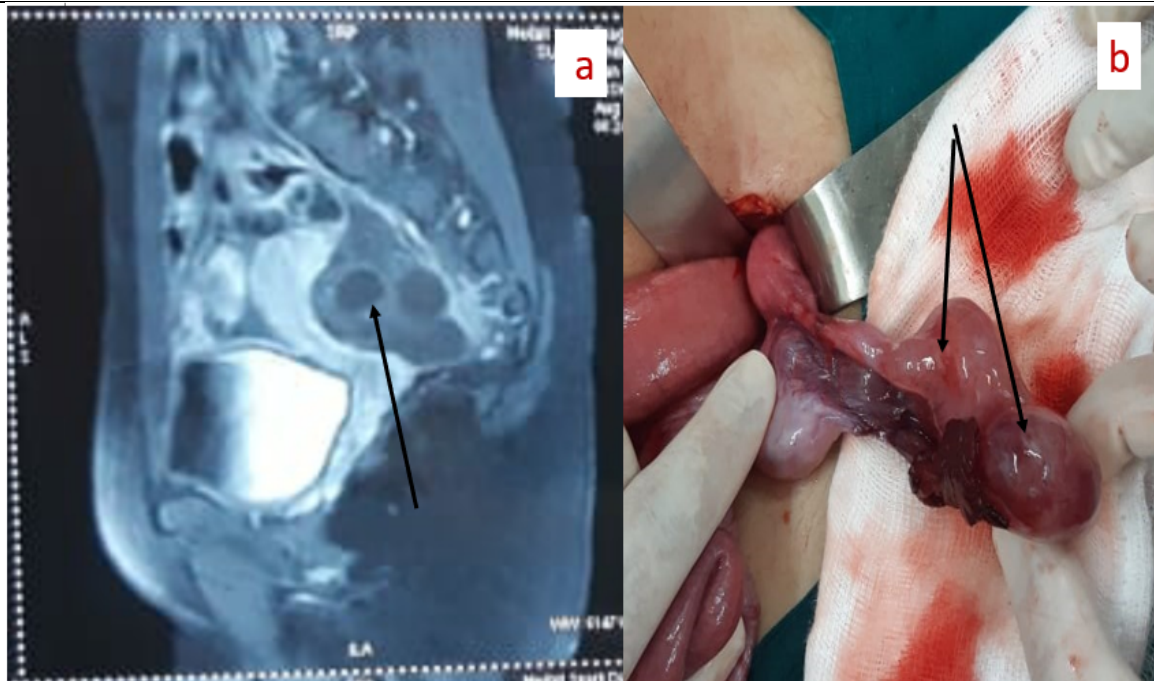


Fig 3: Para ovarian cyst: a): MRI image of bilobed para ovarian cyst
b): Intra operative image

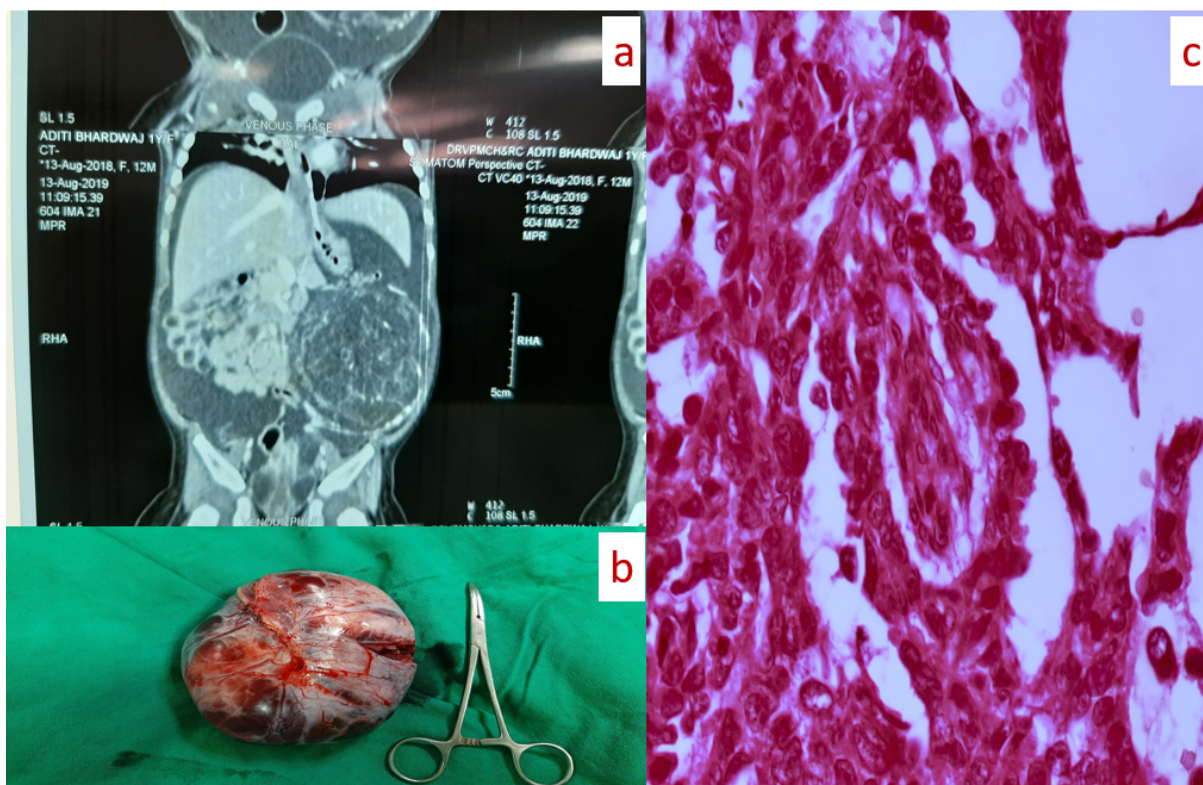


Fig 4: Yolk Sac Tumour:

- a. CT scan image
- b. Operative specimen
- c. Histopathology image showing papillary glands lined by atypical columnar cells showing large pleomorphic, hyperchromatic nuclei.

DISCUSSION

Adnexal masses originate from ovaries, uterus, fallopian tubes and the connecting tissue. Adnexal masses in paediatric patients are uncommon but not rare. Approximately 2/3rd of adnexal masses are ovarian tumours. Majority of ovarian masses seen in

premenarchal girls are benign lesions, less than 10% are malignant (Khedkar, K. *et al.*, 2016).

In our series 60% patients had Simple Follicular Cysts and 30% had Dermoid Cysts. (**Table 2**).

Table 1: Age distribution:

Age	0-12 mon	1-5 yrs	5-12 yrs
Simple cyst	4		
Dermoid			1
Cyst with Torsion			10
Ovarian Torsion			2
Para Ovarian cyst with Torsion			1
With Hypothyroidism & Torsion			1
Malignant Teratoma		1	

Diagnosis of ovarian masses may be delayed or even missed because of low index of suspicion, nonspecific complaints &/or consideration of more common acute abdominal causes that mimic adnexal issues. Differential Diagnosis does vary with age.

Contrary to many reported cases in adolescent age group, 75% of our patients were between 5 to 12 years of age. (**Table 1**).

Table 2: Distribution of cases as per their final diagnosis was as follows:

Simple cysts	10	With Torsion	6
		Antenatally Detected & Conserved	2
		With Hypothyroidism	1
		Elective Surgery	1
Dermoid Cysts	6	Torsion	5
		Elective Surgery	1
Para ovarian cyst			1
Ovarian Torsion			2
Malignancy			1

Oltman *et al.*, had suggested that torsion was responsible for one third of all operative ovarian cases, especially if there is an underlying mass larger than 5cm in size (Oltmann, S. C. *et al.*, 2009). In our series, as many as 70% patients presented with torsion.

USG Abdomen was a good screening test and positive Whirlpool sign on colour doppler corroborated well with intraoperative finding of ovarian torsion (Valsky, D. V. *et al.*, 2010).

Teratomas are composed of tissues originating from Endoderm, Mesoderm and Ectoderm in various combinations. Our incidence of mature teratomas was 30% though the reported incidence is 15% (Malingos, S. *et al.*, 2004).

3 types of Dermoid cysts are reported- cystic, solid or monodermal (Malingos, S. *et al.*, 2004).

In mature teratomas or what are commonly known as Dermoid cysts, Ectodermal elements such as skin, hair, sweat and sebaceous glands predominate.

We had two patients with Ovarian Torsion without any underlying cystic lesion. Ovarian torsion refers to

complete or partial rotation of ovary on its ligamentous support often resulting in impedance of its blood supply. The ovary is not a fixed organ, but is suspended by Infundibulo-pelvic ligament or Suspensory ligament of ovary which is a fold of the broad ligament attached laterally to the pelvic side wall and contains the ovarian vessels. Premenarchal girls with elongated infundibulo-pelvic ligaments are prone to ovarian torsion in normal ovaries (Valsky, D. V. *et al.*, 2010). As puberty is attained and ligaments shorten, occurrence of torsion reduces. Other support structure of the ovary is the Utero-ovarian ligament which attaches the ovary to the uterus and broad ligament. Oophoropexy or Fixation of the ovary is recommended as there is a risk of recurrence after Detorsion. Torsion is more likely to occur on right side, possibly due to the protective effect of sigmoid colon on left side (Huan, C. *et al.*, 2017). Both our ovarian torsion patients had affection on right side. Once there is loss of ovary due to torsion, contralateral ovary is at the risk of asynchronous torsion, hence the other ovary also has to be fixed (Hartley, J. *et al.*, 2018). Methods of Oophoropexy include fixation to the lateral pelvic wall or to the posterior wall of the uterus and plication of the utero-ovarian ligament (Huan, C. *et al.*, 2017). A combination of the two is preferred but in children

fixation to the lateral pelvic wall is most commonly done.

A simple ovarian cyst is one which is unilocular, fluid filled with no septations and solid areas. It is most probably due to the effect of maternal gonadotrophins. 3 to 7 % of all routine antenatal USGs will have ovarian cysts in the foetuses (Kurtoglu, E. *et al.*, 2014).

Simple follicular ovarian cysts less than 5cm in size should be conserved as majority are known to regress. They should be kept under monthly USG surveillance (Kurtoglu, E. *et al.*, 2014). We too had positive result after conserving two such neonates.

Larger cysts pose the risk of torsion due to their sheer weight. Hence this risk must be weighed against the probability of cyst regression while conserving cysts larger than 5cm in size. The decision to intervene must be based on cyst size, USG characteristics and clinical symptoms.

Treatment options are conservative management, cyst aspiration, laparoscopic cystectomy and laparotomy (Guideline for the management of ovarian cysts in children and adolescents 2018). All attempts should be made to save the ovary and perform a cystectomy rather than oophorectomy. In children it is especially important as they require sufficient oestrogen for pubertal surge as well as future fertility (Bryant, A. E., & Laufer, M. R. 2004).

In our series 12 oophorectomies were performed, this number seems somewhat higher compared to published data and calls for introspection. Congested, dusky ovary should be given sufficient time intraoperatively for restoration of its blood supply.

Long term follow-up of these girls regarding attainment of menarche, development of puberty, and their obstetric career is a must. This is severely lacking in our patients, especially those done in teaching institutes. Parents show complete apathy towards routine long-term follow-up once the child recovers from surgery and do not report even after being contacted repeatedly.

Malignant ovarian tumours comprise less than 1% of paediatric malignancy (Mukhopadhyay, M. *et al.*, 2013). They are usually suspected on first USG when a complex cyst with solid areas is reported. Contrast CT scan and metastatic work up is warranted in such patients. For all complex cysts, Tumour Markers are needed to rule out Malignant Germ Cell tumours and should include AFP, Beta hCG, CA-125, CEA and LDH. We had one patient of Yolk Sac Tumour with raised AFP of 1 Lac Units. It has been suggested that AFP levels do not correlate with either stage or grade of the tumour (Khedkar, K. *et al.*, 2016).

Von Wyk- Grumbach Syndrome (described in 1960) is a rare condition characterised by features of precocious puberty like breast development, uterine bleeding along with multiple cysts in both ovaries in the presence of longstanding primary hypothyroidism (Gupta, J., & Lin-Su, K. 2020). Tumour markers like AFP may be elevated. After initiating thyroxine replacement therapy, the cysts usually regress and markers return to normal. Catastrophic outcome in our patient reflects lacunae in our health care system and indicates the lack of proper record keeping and follow-up.

CONCLUSIONS

Incidence of ovarian cysts in premenarchal girls is on the rise. Simple follicular cyst followed by Dermoid cyst are the common pathological findings.

Foetal and neonatal ovarian cysts are likely to arise from ovarian stimulation by maternal gonadotrophins. Mothers who take some form of hormonal treatment tend to have babies born with ovarian cysts.

Majority of our patients presented with acute abdomen due to torsion. Hence it is important to consider adnexal pathology in differential diagnosis of acute abdomen in paediatric patients. Most of these patients landed up with oophorectomy which highlights that the small window period when the ovary might have been viable, has been missed often. Early diagnosis and prompt surgical intervention are necessary to reduce loss of ovary. Ovary sparing surgery was possible in limited settings. Decision to go ahead with oophorectomy should be delayed until a congested, engorged ovary fails to recover inspite of adequate intraoperative measures aimed at restoring viability.

Infrastructure and technical expertise for laparoscopy in emergency setting for paediatric patients is still lacking, at least in Tier 2 city like ours, in India.

Importance of long-term follow-up should be emphasised during counselling sessions with parents.

REFERENCES

1. Khedkar, K., Shah, H., Tiwari, C., Makhija, D., & Waghmare, M. (2016). Our experience with Adnexal masses. *Inter Jour of Ped and Ado Medi* 3, 169-174
2. Oltmann, S. C., Fischer, A., Barber, R., Huang, R., Hicks, B., & Garcia, N. (2009). Cannot exclude torsion—a 15-year review. *Journal of pediatric surgery*, 44(6), 1212-1217.
3. Malingos, S., Protopapas, D., Drakakis, P., Liapi, A., Loutradis, D., Rodalakis, A., et al. (2004). Laparoscopic treatment of ovarian dermoid cysts: 11-year experience. *J Am Assoc Gynecol Laparosc* 11, 478-85

4. Valsky, D. V., Esh-Broder, E., Cohen, S. M., Lipschuetz, M., & Yagel, S. (2010). Added value of the gray-scale whirlpool sign in the diagnosis of adnexal torsion. *Ultrasound in Obstetrics and Gynecology*, 36(5), 630-634.
5. Huan, C., Hong, M.K., & Ding, D.C. (2017). A review of ovary torsion. *Tzu- Chi Medical Journal* 29 (3), 143-147
6. Hartley, J., Akhtar, M., & Edi-Osagie, E. (2018). Oophoropexy for recurrent ovarian torsion. *Case reports in obstetrics and gynecology*, 2018.
7. Kurtoglu, E., Kokcu, A., & Danaci, M. (2014). Asynchronous bilateral ovarian torsion. A case report and mini review. *Journal of pediatric and adolescent gynecology*, 27(3), 122-124.
8. Bryant, A. E., & Laufer, M. R. (2004). Fetal ovarian cysts: incidence, diagnosis and management. *The Journal of reproductive medicine*, 49(5), 329-337.
9. Guideline for the management of ovarian cysts in children and adolescents (2018). Britspag.org, 2018. The British Society of Paediatric and Adolescent Gynaecology.
10. Mukhopadhyay, M., Shukla, R. M., Mukhopadhyay, B., Mandal, K. C., Ray, A., Sisodiya, N., & Patra, M. P. (2013). Ovarian cysts and tumors in infancy and childhood. *Journal of Indian Association of Pediatric Surgeons*, 18(1), 16-19
11. Gupta, J., & Lin-Su, K. (2020). Van Wyk-Grumbach syndrome in a female pediatric patient with trisomy 21: a case report. *International journal of pediatric endocrinology*, 2020(1), 2.