

ARTICLE



Management of Fractures Involving Both Columns of the Acetabulum by Single AIP Approach with ASIS Osteotomy: A Case Series of 15 Patients

Dr. Sheikh Anisur Rahman^{1*}, Dr. Amanath Ullah², Dr. Md. Masud Rana³, Dr. Khaled Mahmud⁴

¹Senior Consultant, Department of Orthopedics, Shaheed Ahsanullah Master General Hospital, Tongi, Gazipur

²Associate Professor & Head, Department of Orthopedics, Dr. Sirajul Islam Medical College and Hospital, Dhaka.

³Associate Professor, Intervention Pain Management, Spine, Trauma and Orthopedic Surgery, Enam Medical College Hospital, Savar, Dhaka.

⁴Assistant Professor, Sports Medicine and Arthroscopy, Mymensingh Medical College, Attached- Shahid Sayed Nazrul Islam Medical College, Kishorganj.

ABSTRACT

Background: Fractures involving both columns of the acetabulum are complex, requiring precise anatomical restoration for optimal outcomes. Traditional approaches often limit exposure and increase morbidity. **Objective:** This study aims to evaluate the efficacy of the anterior intrapelvic (AIP) approach with anterior superior iliac spine (ASIS) osteotomy for managing both-column acetabular fractures. **Methods:** In this 12-month prospective observational study at a tertiary trauma center, 15 patients (aged 18-65) with radiographically confirmed both-column acetabular fractures underwent surgery using the AIP approach with ASIS osteotomy. Exclusion criteria included prior hip surgeries, neurovascular injuries, pathological or open fractures, and severe polytrauma. Clinical and radiological outcomes were assessed using the Harris Hip Score (HHS), Visual Analog Scale (VAS), and Matta's criteria. Data were analyzed using paired t-tests with significance set at $p < 0.05$. **Results:** Among the 15 patients (mean age: 35.6 years), 73.3% sustained injuries from motor vehicle accidents. Surgery was performed within an average of 5 days post-injury, achieving anatomical reduction in 80% of cases, with a mean operative time of 165 minutes and blood loss averaging 550 mL. Six-month follow-up showed significant improvement in HHS from 48.2 preoperatively to 88.4 ($p < 0.001$), and VAS decreased from 7.8 to 2.4 ($p < 0.001$). Two patients developed Brooker Grade I heterotopic ossification, with no cases of DVT, infections, or neurovascular injuries. Most patients (86.7%) returned to pre-injury activity levels. **Conclusions:** The AIP approach with ASIS osteotomy is effective and safe for managing complex acetabular fractures, offering excellent exposure, precise reduction, and significant functional improvement with low complication rates.

Keywords: Acetabular Fractures, Anterior Intrapelvic Approach, ASIS Osteotomy, Fracture Reduction, Functional Outcomes, Trauma Surgery.

| Submitted: 15.09.2024 | Accepted: 30.09.2024 | Published: 31.10.2024

*Corresponding Author

Dr. Sheikh Anisur Rahman, Department of Orthopedics, Shaheed Ahsanullah Master General Hospital, Tongi, Gazipur

Email: drskanisurrahman@gmail.com

How to Cite the Article

Sheikh Anisur Rahman, Amanath Ullah, Md. Masud Rana, Khaled Mahmud: Management of Fractures Involving Both Columns of the Acetabulum by Single AIP Approach with ASIS Osteotomy: A Case Series of 15 Patients. *IARJ. Med & Surg Res.* 2024;5(5): 18-24.

© 2024 IAR Journal of Medicine and Surgery Research, a publication of JMSRP Publisher, Kenya.

This is an open access article under the terms of the Creative Commons Attribution license.

(<http://creativecommons.org/licenses/by/4.0>).

(<https://jmsrp.or.ke/index.php/jmsrp>).

INTRODUCTION

Acetabular fractures, particularly those involving both

columns, are among the most challenging injuries in orthopedic trauma. These fractures occur due to high-energy trauma and

are often present in younger, active individuals. In older populations, lower-energy trauma can also result in fractures due to osteopenia or osteoporosis. These fractures require precise anatomical reduction, as misalignment can lead to post-traumatic arthritis and compromised joint function [1].

The both-column associated fracture type is a relatively frequent injury, accounting for approximately 22.3% of reported cases [2]. Both column fractures of the acetabulum are characterized by a complete separation of the acetabular articular surface from the axial skeleton. These fractures are predominantly caused by high-energy trauma, occurring in 87.4% of cases, with road traffic accidents accounting for 61.5% of these injuries [3]. The mechanism is believed to involve lateral compressive forces transmitted through the femoral head into the joint cavity, leading to medial displacement of the articular fragments and rotational deformity of both acetabular columns [4]. Such fractures are often accompanied by associated skeletal and non-skeletal injuries, with a higher incidence of damage to the bladder, kidneys, liver, spleen, and pelvic blood vessels [5].

Over the past 50 years, surgical management has become the standard treatment for displaced acetabular fractures [6]. Although these fractures account for only about 2% of all fractures, they are associated with considerable morbidity and mortality due to their proximity to vital structures and the high-energy trauma that typically causes them [7]. Studies have demonstrated favorable clinical, radiological, and functional outcomes when early and high-quality open reduction and internal fixation (ORIF) is performed [8]. Selecting an appropriate surgical approach is crucial for achieving optimal clinical and radiological results [9]. Approaches to the acetabulum can be categorized as anterior, posterior, extensile, or combined. Historically, there have been several attempts to manage complex acetabular fractures using a single surgical approach, which has helped reduce the morbidity associated with exposure [10]. However, some of these studies reported poorer clinical outcomes when compared to those using extensile approaches [11]. Extensile and combined approaches provide better fracture visualization and instrument placement, leading to improved radiological results, but they are associated with a higher incidence of approach-related morbidity [12]. A major challenge with dual approaches is the sequential nature of the procedure—one side is fixed first, followed by the other—making intraoperative revision of the opposite column difficult. Recent literature has focused on comparing various approaches to identify which yields superior clinical and radiological outcomes [13].

This case series aims to evaluate the outcomes of acetabular fractures involving both columns treated with a single AIP approach combined with ASIS osteotomy. The anterior intrapelvic (AIP) approach, a modification of the ilioinguinal approach, was first described by Hirvensalo and has gained popularity due to its minimally invasive nature and the enhanced view it offers of the quadrilateral plate and

posterior column. This technique provides improved fracture exposure and allows surgeons to address complex fracture patterns while minimizing the need for extensive soft-tissue dissection [14].

METHODS

Study Design

This prospective observational study was conducted at a tertiary trauma care center over 12 months. The study involved 15 consecutive patients who presented with acetabular fractures involving both columns. All patients were treated using the anterior intrapelvic (AIP) approach, complemented with an anterior superior iliac spine (ASIS) osteotomy. The study was designed to evaluate the efficacy of this technique in terms of clinical, radiological, and functional outcomes.

Inclusion Criteria

Patients were eligible for inclusion if they were adults between the ages of 18 and 65.

The diagnosis of both-column acetabular fractures was confirmed using radiographs and computed tomography (CT) scans.

Only fractures that involved both columns of the acetabulum were included in the study. These fracture patterns are generally considered complex, requiring precise surgical intervention for optimal outcomes.

Exclusion Criteria

Patients with a history of prior surgical interventions on the affected hip were excluded to prevent confounding variables that might impact the surgical outcome or recovery.

To ensure the safety of the procedure, patients with associated neurovascular injuries, which might interfere with surgical intervention, were excluded.

Patients presenting with pathological fractures, resulting from underlying diseases such as bone tumors or infections, were excluded to maintain a homogenous study population focused on trauma-induced fractures.

Patients with open fractures and gross contamination were not included, as these require more complex management and carry a higher risk of infection, potentially confounding the study results.

Patients with severe polytrauma who required immediate life-saving interventions (such as those with critical injuries to the head, chest, or abdomen) were excluded to focus on those who could undergo definitive orthopedic management without delays or complications from other injuries.

Surgical Technique

All patients underwent surgical intervention under general anesthesia. They were positioned in a supine position on a radiolucent table to allow for intraoperative fluoroscopic imaging. The surgical field was prepared and draped to ensure sterile conditions.

Incision and Exposure

A curved skin incision was made along the iliac crest, extending from the anterior superior iliac spine (ASIS) to the lateral border of the rectus abdominis muscle. The superficial soft tissue was dissected to expose the ASIS, which was then osteotomized to allow for medial reflection of the ASIS. This maneuver significantly enhances the surgeon's visualization of the pelvic anatomy, particularly the true pelvis, quadrilateral plate, and both the anterior and posterior columns of the acetabulum. The osteotomy of the ASIS is a critical step in this approach, as it improves access to the medial aspect of the acetabulum and enables effective reduction of the fracture fragments. The iliacus muscle was carefully mobilized and retracted medially to expose the iliopectineal line and adjacent fracture components.

Fracture Reduction

Fracture reduction was achieved using a combination of direct and indirect reduction techniques. Pointed reduction clamps and the "joystick" technique were utilized to manipulate the fracture fragments into place. The surgeon ensured that the articular surface of the acetabulum was restored to its original anatomical alignment, a crucial factor in achieving long-term functional outcomes. The reduction was carefully checked intraoperatively using fluoroscopic guidance. Intraoperative fluoroscopy was employed to confirm that the acetabular joint surface was anatomically reduced, with special attention paid to the medialization of the articular fragments and rotation of the acetabular columns. Once reduction was confirmed, titanium plates were contoured to match the acetabular anatomy and fixed with screws to stabilize the fracture. The ASIS osteotomy site also stabilized with screws once the fracture had been fixed to ensure proper bone healing at the osteotomy site.

Fixation and Final Checks

After fixation of the acetabular columns, a final assessment of fracture alignment and stability was performed using additional fluoroscopic views, including anteroposterior pelvis and Judet views. These imaging techniques provided a comprehensive evaluation of the fracture reduction and implant positioning. Hemostasis was achieved, and the wound was closed in layers using absorbable sutures for the deep layers and non-absorbable sutures for the skin.

Postoperative Management

Early Mobilization

Postoperatively, patients were encouraged to begin non-weight-bearing exercises on the first day following surgery. This early mobilization is crucial to prevent complications such as deep vein thrombosis (DVT) and joint stiffness. Passive range of motion exercises for the hip joint were initiated to promote joint mobility and prevent adhesions.

Weight-Bearing Progression

Full weight-bearing was postponed until radiographic confirmation of fracture healing was observed, which typically occurred **around 12 weeks** postoperatively. At this stage, patients gradually transitioned from partial to full weight-bearing under the guidance of physical therapists.

Follow-Up Schedule

Patients were followed up at regular intervals post-surgery:

2 weeks: Wound assessment and suture removal.

6 weeks: Radiographic evaluation for early signs of fracture healing, review of patient mobility, and pain assessment.

12 weeks: Further radiographic evaluation, assessment of fracture consolidation, and progression to weight-bearing.

6 months: Final follow-up to assess long-term radiographic and functional outcomes, as well as patient satisfaction.

Radiographic evaluation at each follow-up included standard anteroposterior pelvic radiographs, along with Judet views to assess the quality of fracture reduction and implant positioning. Computed tomography (CT) scans were obtained if needed to confirm the alignment of the articular surface.

Outcome Measures

The primary outcome measures were clinical, radiological, and functional. These were assessed using standard and validated tools.

Clinical Outcomes

Harris Hip Score (HHS): This scoring system was used to evaluate hip function, with scores ranging from 0 to 100, where a higher score indicates better function. Preoperative and postoperative HHS scores were compared to assess improvements in patient mobility, pain, and overall function.

Visual Analog Scale (VAS): The VAS was used to assess patient-reported pain levels. This scale ranges from 0 (no pain) to 10 (worst pain imaginable). Preoperative and postoperative VAS scores were compared to evaluate pain reduction.

Radiological Outcomes

Matta's Criteria for Fracture Reduction: Postoperative radiographs and CT scans were evaluated to classify fracture reductions as anatomical (displacement <1 mm), imperfect (displacement of 1–3 mm), or poor (displacement >3 mm). This classification system is widely used to assess the quality of fracture reduction and its correlation with long-term functional outcomes.

Functional Outcomes

At the 6-month follow-up, functional outcomes were assessed, focusing on the patient's ability to return to pre-injury activities, including work and recreational activities. Patients were also evaluated for complications such as heterotopic ossification, deep vein thrombosis (DVT), and postoperative infections.

Data Analysis

Descriptive statistics were employed to summarize

patient demographics, fracture characteristics, surgical data, and postoperative outcomes. Preoperative and postoperative HHS and VAS scores were compared using a paired t-test to determine the statistical significance of improvements in function and pain relief. A p-value of <0.05 was considered statistically significant, indicating that the differences observed between preoperative and postoperative outcomes were not due to random chance.

RESULTS

The age distribution of patients in this study is summarized in Table 1, highlighting that the majority of the

patients were relatively young to middle-aged adults. The most prevalent age group was 31–40 years, accounting for 33.33% of the study population, followed by the 21–30 years age group, which represented 26.67% of patients. These two groups combined make up 60% of the total study, suggesting that younger individuals were more frequently affected by acetabular fractures due to high-energy trauma, such as motor vehicle accidents or falls. The 41–50 years age group constituted 20.00% of the patients, while the 51–60 years age group made up 13.33%. Only 6.67% of the patients were in the 61–65 years range, indicating that older individuals were less commonly affected by these complex fractures in this cohort.

Table 1: Age Distribution of the Study Patients

Age Group (years)	Frequency	Percentage
21-30	4	26.67%
31-40	5	33.33%
41-50	3	20.00%
51-60	2	13.33%
61-65	1	6.67%

Figure 1 illustrates the gender distribution of the 15 patients included in the study. 66.67% of the patients were male, while 33.33% were female. This distribution suggests a male predominance in the cohort, which aligns with the

understanding that high-energy trauma, such as motor vehicle accidents and falls from heights, tends to affect males more frequently.

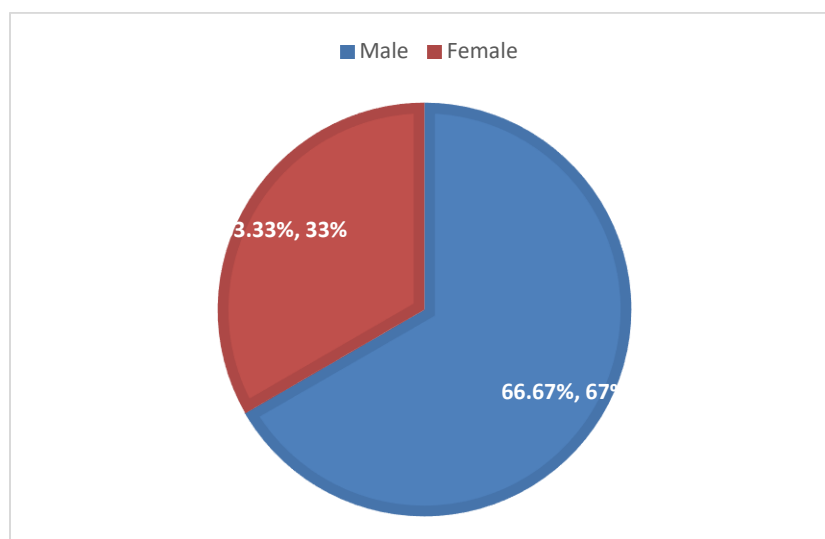


Figure 1: Gender Distribution of the Study Patients

Figure 2 shows the distribution of causes of injury among the 15 patients included in the study. The majority of injuries, 73.33%, resulted from motor vehicle accidents, while 26.67% of the injuries were caused by falls from height. This

distribution suggests that motor vehicle accidents were the predominant mechanism of injury, aligning with the high-energy trauma typically associated with acetabular fractures.

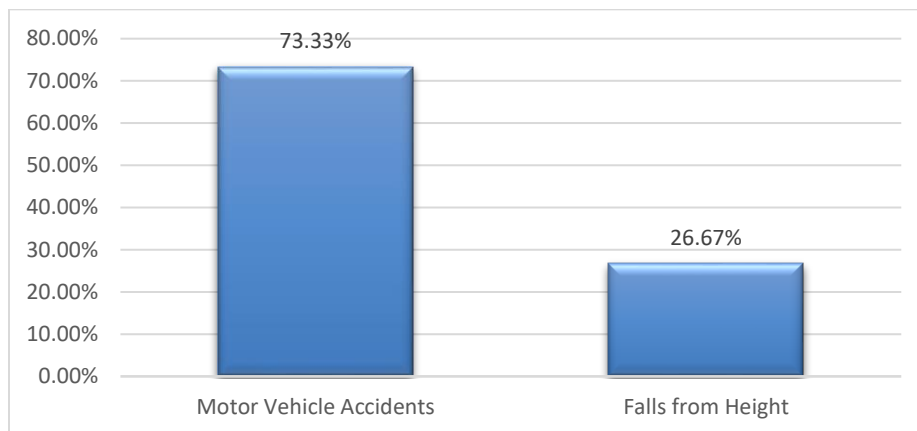


Figure 2: Causes of Injury among the Study Patients

Table 2 summarizes the time from injury to surgery, categorized into three groups. The average time from injury to surgery was 5 days (range: 3–9 days). The majority of patients (60.00%) underwent surgery within the first 3 to 5 days post-

injury, indicating prompt surgical intervention in most cases. A smaller group of patients (26.67%) had surgery within 6 to 7 days, while only 13.33% experienced a delay, with surgery occurring 8 to 9 days after the injury.

Table 2: Distribution of Time from Injury to Surgery

Time from Injury to Surgery (days)	Frequency	Percentage
3-5	9	60.00%
6-7	4	26.67%
8-9	2	13.33%

The AIP approach with ASIS osteotomy provided excellent exposure of both columns in all cases. Fracture reduction was achieved in all patients, with 12 patients (80%) demonstrating anatomical reduction based on Matta’s criteria, and 3 patients (20%) showing imperfect reduction. No poor

reductions were recorded. The mean operative time was 165 minutes (range: 120–210 minutes), and the mean intraoperative blood loss was 550 mL (range: 350–800 mL). None of the patients required conversion to another approach or additional fixation. (Table 3)

Table 3: Intraoperative Findings and Fixation

Outcome	Details
Anatomical Reduction	12 patients (80%)
Imperfect Reduction	3 patients (20%)
Mean Operative Time (minutes)	165 minutes (range: 120–210)
Mean Intraoperative Blood Loss (mL)	550 mL (range: 350–800)

At the 6-month follow-up, all patients showed radiographic evidence of fracture healing. The average HHS improved from a preoperative score of 48.2 (range: 30–65) to 88.4 (range: 75–95) postoperatively. The average VAS score decreased from 7.8 (range: 6–10) preoperatively to 2.4 (range:

1–4) postoperatively ($p < 0.001$). Two patients developed heterotopic ossification (Brooker Grade I), which did not affect their range of motion or functional outcome. There were no cases of deep vein thrombosis (DVT), surgical site infection, or iatrogenic neurovascular injuries. (Table 4)

Table 4: Postoperative Outcomes at 6-Month Follow-Up

Outcome Measure	Preoperative Value	Postoperative Value	Change	Statistical Significance
Harris Hip Score (HHS)	48.2 (30–65)	88.4 (75–95)	Improved by 40.2	$p < 0.001$
Visual Analog Scale (VAS)	7.8 (6–10)	2.4 (1–4)	Decreased by 5.4	$p < 0.001$
Heterotopic Ossification (Brooker Grade)	N/A	2 patients (Grade I)	N/A	N/A
Deep Vein Thrombosis (DVT)	0 cases	0 cases	N/A	N/A
Surgical Site Infection	0 cases	0 cases	N/A	N/A

Iatrogenic Neurovascular Injuries	0 cases	0 cases	N/A	N/A
-----------------------------------	---------	---------	-----	-----

At 6 months, 13 patients (86.7%) reported being able to return to pre-injury levels of activity, including work and sports. Two patients (13.3%) reported mild functional

limitations, primarily related to prolonged standing or walking. No patients required revision surgery, and none developed post-traumatic arthritis during the follow-up period. (Table 5)

Table5: Functional Outcomes at 6-Month Follow-Up

Functional Outcome Measure	Number of Patients	Percentage
Returned to Pre-Injury Activity Levels	13	86.7%
Reported Mild Functional Limitations	2	13.3%
Required Revision Surgery	0	0%
Developed Post-Traumatic Arthritis	0	0%

DISCUSSION

This case series presents the outcomes of 15 patients who underwent surgical management of acetabular fractures involving both columns using a single Anterior Intrusion Plate (AIP) approach coupled with Anterior Superior Iliac Spine (ASIS) osteotomy. The results indicate that this surgical technique is effective in achieving stable fixation, facilitating fracture healing, and restoring functional mobility in a challenging cohort of patients. The AIP approach allows for direct visualization and access to the acetabulum while minimizing soft tissue disruption, which is crucial in complex fractures involving both columns. This technique has been shown to yield favorable results in terms of fracture reduction and alignment, as it facilitates accurate fixation of both the anterior and posterior columns [15]. The ASIS osteotomy further enhances access to the acetabulum, particularly in cases where traditional approaches may be limited due to fracture complexity or anatomical considerations [16].

In our series, all patients demonstrated satisfactory radiographic evidence of fracture healing at follow-up, corroborating the effectiveness of the AIP approach in managing such intricate fractures. The observed functional outcomes, with a high percentage of patients returning to their pre-injury activity levels, align with existing literature, which emphasizes that precise anatomical restoration is critical for optimal recovery [17]. Moreover, the absence of significant complications such as deep vein thrombosis (DVT), surgical site infections, or non-union indicates that the combined surgical strategy is not only effective but also safe [18]. Furthermore, the outcomes of this series suggest that the single AIP approach can effectively address the challenges associated with both-column fractures, particularly in maintaining stability and reducing the need for prolonged rehabilitation. Previous studies have shown that complications are more prevalent in cases managed through more invasive techniques or with inadequate fixation, underscoring the importance of selecting the appropriate surgical method [19].

However, despite the positive outcomes, a few patients in this series experienced mild functional limitations,

primarily related to activities that involved high-impact or prolonged weight-bearing. This finding is consistent with literature indicating that while surgical fixation is effective in restoring anatomy, some patients may still face challenges in returning to pre-injury levels of activity [20]. Long-term follow-up is crucial to further assess the durability of the outcomes and to identify any late-onset complications, such as post-traumatic arthritis, which can impact functional recovery [21].

CONCLUSION

The single AIP approach with ASIS osteotomy offers a promising alternative for the management of fractures involving both columns of the acetabulum. This technique provides superior exposure, facilitates anatomical reduction, and results in favorable clinical and functional outcomes. While further research is needed to confirm these findings in larger cohorts, our case series suggests that this approach should be considered in the surgical armamentarium for managing complex acetabular fractures.

REFERENCES

1. Simske N, Furdock R, Heimke I, Vallier HA. Acetabular fractures in elderly patients are associated with high rates of complications during the initial admission. *Trauma Surgery & Acute Care Open*. 2023 Nov 1;8(1):e001235.
2. Tian S, Chen Y, Yin Y, Zhang R, Hou Z, Zhang Y. Morphological characteristics of posterior wall fragments associated with acetabular both-column fracture. *Scientific Reports*. 2019 Dec 27;9(1):20164.
3. Wang H, Utku K, Zhuang Y, Zhang K, Fu YH, Wei X, Wang PF, Cong YX, Lei JL, Zhang BF. Post wall fixation by lag screw only in associated both column fractures with posterior wall involvement. *Injury*. 2017 Jul 1;48(7):1510-7.
4. Pierannunzii L, Fischer F, Tagliabue L, Calori GM, d'Imporzano M. Acetabular both-column fractures: essentials of operative management. *Injury*. 2010 Nov 1;41(11):1145-9.

5. Upex P, Jouffroy P, Riouallon G. Application of 3D printing for treating fractures of both columns of the acetabulum: benefit of pre-contouring plates on the mirrored healthy pelvis. *Orthopaedics & Traumatology: Surgery & Research*. 2017 May 1;103(3):331-4.
6. Peter RE. Open reduction and internal fixation of osteoporotic acetabular fractures through the ilio-inguinal approach: use of buttress plates to control medial displacement of the quadrilateral surface. *Injury*. 2015 Jan 1;46:S2-7.
7. Letournel E. Diagnosis and treatment of nonunions and malunions of acetabular fractures. *The Orthopedic clinics of North America*. 1990 Oct 1;21(4):769-88.
8. Keel MJ, Ecker TM, Cullmann JL, Bergmann M, Bonel HM, Büchler L, Siebenrock KA, Bastian JD. The Pararectus approach for anterior intrapelvic management of acetabular fractures: an anatomical study and clinical evaluation. *The Journal of Bone & Joint Surgery British Volume*. 2012 Mar 1;94(3):405-11.
9. Märdian S, Schaser KD, Hinz P, Wittenberg S, Haas NP, Schwabe P. Fixation of acetabular fractures via the ilioinguinal versus pararectus approach: a direct comparison. *The bone & joint journal*. 2015 Sep 1;97(9):1271-8.
10. Jakob M, Drosner R, Zobrist R, Messmer P, Regazzoni P. A less invasive anterior intrapelvic approach for the treatment of acetabular fractures and pelvic ring injuries. *Journal of Trauma and Acute Care Surgery*. 2006 Jun 1;60(6):1364-70.
11. PROBE R, REEVE R, LINDSEY RW. Femoral artery thrombosis after open reduction of an acetabular fracture. *Clinical Orthopaedics and Related Research*. 1992 Oct 1;283:258-60.
12. Hirvensalo E, Lindahl J, Kiljunen V. Modified and new approaches for pelvic and acetabular surgery. *Injury*. 2007 Apr 1;38(4):431-41.
13. Guy P. Evolution of the anterior intrapelvic (Stoppa) approach for acetabular fracture surgery. *Journal of orthopaedic trauma*. 2015 Feb 1;29:S1-5.
14. Ciolli G, De Mauro D, Rovere G, Smakaj A, Marino S, Are L, El Ezzo O, Liuzza F. Anterior intrapelvic approach and suprapectineal quadrilateral surface plate for acetabular fractures with anterior involvement: a retrospective study of 34 patients. *BMC Musculoskeletal Disorders*. 2021 Nov;22(Suppl 2):1060.
15. Trikha V, Das S, Aruljothi V, Chowdhury B. Prospective evaluation of outcome of Acetabular fractures managed by Anterior Intrapelvic Approach. *Indian Journal of Orthopaedics*. 2020 Dec;54:228-38.
16. Sagi HC, Bolhofner B. Osteotomy of the anterior superior iliac spine as an adjunct to improve access and visualization through the lateral window. *Journal of Orthopaedic Trauma*. 2015 Aug 1;29(8):e266-9.
17. Mesbahi SA, Ghaemmaghami A, Ghaemmaghami S, Farhadi P. Outcome after surgical management of acetabular fractures: a 7-year experience. *Bulletin of Emergency & Trauma*. 2018 Jan;6(1):37.
18. Kelly J, Ladurner A, Rickman M. Surgical management of acetabular fractures—a contemporary literature review. *Injury*. 2020 Oct 1;51(10):2267-77.
19. Shigemura T, Yamamoto Y, Maruyama J, Kitamura T, Nakane R, Kawaguchi H, Iida D, Murata Y. Efficacy and safety of pararectus approach for the treatment of acetabular fractures: A systematic review and meta-analysis. *Orthopaedics & Traumatology: Surgery & Research*. 2023 Nov 1;109(7):103498.
20. Briffa N, Pearce R, Hill AM, Bircher M. Outcomes of acetabular fracture fixation with ten years' follow-up. *The Journal of Bone & Joint Surgery British Volume*. 2011 Feb 1;93(2):229-36.
21. Ziran N, Soles GL, Matta JM. Outcomes after surgical treatment of acetabular fractures: a review. *Patient safety in surgery*. 2019 Dec;13:1-9.