

ARTICLE



Outcome of Lumbar Interbody Fusion and Posterior Instrumentation in Spondylolisthesis

Dr. Md. Mizanur Rahman^{1*}, Dr. A M Mohiuddin², Dr. Aashik Salauddin³, Dr. Tanzin Bin Kashem⁴, Dr. Md. Shofiqul Islam⁵, Dr. Md. Abul Ahsan⁶, Dr. Muhammad Ali Choudhary⁷, Dr. Mustaq Ahmed⁸

¹ Junior Consultant, Department of Orthopaedic Surgery, Upazila Health Complex, Manda, Naogaon

² Junior Consultant, Department of Orthopaedic Surgery, 250 Bedded district Sadar Hospital, Sherpur

³ Junior Consultant, Department of Orthopaedic Surgery, Upazila Health Complex, Rupganj, Narayanganj

⁴ IMO, Department of Orthopaedic Surgery, Dhaka Medical College Hospital, Dhaka

⁵ Junior Consultant, Department of Paediatrics, Upazila Health Complex, Manda, Naogaon

⁶ Junior Consultant, Department of Anaesthesia, Upazila Health Complex, Bagha, Rajshahi

⁷ Junior Consultant, Department of Anaesthesia, Upazila Health Complex, Manda, Naogaon

⁸ Junior Consultant, Department of Anaesthesia, Upazila Health Complex, Nachole, Chapainawabganj

ABSTRACT

Background: Spondylolisthesis, a prevalent source of low back pain, may require surgery after conservative treatment. Techniques like PLIF, ALIF, and TLIF have distinct benefits; PLIF, notably, provides stabilization and sagittal balance restoration via a single posterior approach. **Objective:** This study aimed to assess the outcomes of Lumbar Interbody Fusion and Posterior Instrumentation in Spondylolisthesis using cages and bone grafts. The study evaluated the impact of lumbar decompression, interbody fusion, and stabilization on patients' conditions. **Methods:** A prospective observational study was conducted at Dhaka Medical College Hospital from January to December 2021, involving 21 patients who underwent the operative procedure. The analysis encompassed the influence of lumbar decompression, interbody fusion using bone graft with cages, and stabilization with pedicle screws and rods on lumbar Spondylolisthesis patients. **Results:** Out of 21 patients, 7(33.3%) were male and 14(66.7%) were female. The mean age was 46.90 ± 13.7 years and range between 23-70 years. The most expected involved level is L4 over L5 17(81.0%). According to Meyerding's grading, grade II was 15(71.4%), and grade I was 6 (28.6%), according to types of Spondylolistheses lytic 12(57.1%), degenerative 8(38.1%), and dysplastic 1 (4.8%). Excellent outcomes were seen in 17(81.0%) cases and good results were found in 4(19.0%) cases. Probably not fused after surgery was observed in 2(9.5%) patients. The preoperative Oswestry Disability Index was 57.78 ± 2.25 , and the postoperative ODI was 16.56 ± 3.53 . **Conclusion:** Instrumented fusion demonstrated higher fusion rates and superior clinical outcomes, suggesting its efficacy in managing lumbar spondylolisthesis.

Keywords: Spondylolisthesis, Lumbar Interbody Fusion, Posterior Instrumentation, Fusion Rates, Clinical Outcome.

| **Submitted:** 15.08.2024 | **Accepted:** 25.09.2024 | **Published:** 31.10.2024

*Corresponding Author

Dr. Md. Mizanur Rahman, Junior Consultant, Department of Orthopaedic Surgery, Upazila Health Complex, Manda, Naogaon
Email: mizanszmc9@gmail.com

How to Cite the Article

Md. Mizanur Rahman, A M Mohiuddin, Aashik Salauddin, Tanzin Bin Kashem, Md. Shofiqul Islam, Md. Abul Ahsan, Muhammad Ali Choudhary, Mustaq Ahmed: Outcome of Lumbar Interbody Fusion and Posterior Instrumentation in Spondylolisthesis. *IARJ. Med & Surg Res.* 2024;5(5): 25-31.

© 2024 IAR Journal of Medicine and Surgery Research, a publication of JMSRP Publisher, Kenya.

This is an open access article under the terms of the Creative Commons Attribution license.

(<http://creativecommons.org/licenses/by/4.0>).

(<https://jmsrp.or.ke/index.php/jmsrp>).

INTRODUCTION

Spondylolisthesis, characterized by the sagittal translational displacement of one vertebra concerning another, has been recognized since the 18th century when Dr. Herbiniaux documented cases with anterior displacement of the superior vertebra over the one below [1]. Derived from the Greek roots "spondyl," meaning spine, and "olisthesis," meaning to slip, the term signifies vertebral displacement. Classification systems, such as that proposed by, categorize spondylolisthesis into six types based on etiology, including congenital, isthmic, degenerative, traumatic, pathologic, and post-surgical varieties [2]. Recent epidemiological studies suggest a prevalence of spondylolisthesis in the adult population of around 5.9%, with conservative therapies proving effective in 85%-90% of cases [3]. However, 10-15% of patients require surgical intervention due to failed conservative treatment. Among the surgical modalities available, lumbar spinal fusion has emerged as an effective treatment for patients experiencing low back and leg pain associated with degenerative lumbar spinal disorders.

Numerous surgical techniques have been developed for lumbar interbody fusion, with or without instrumentation, including posterior lumbar interbody fusion (PLIF), anterior lumbar interbody fusion (ALIF), circumferential 360-degree fusion, and transforaminal lumbar interbody fusion (TLIF) [4]. Among these, PLIF stands out for its advantages, including spinal canal decompression, anterior column reconstruction, decompression of foraminal stenosis, and reduction of sagittal slips, all achievable through a single posterior approach [5]. Traditionally, PLIF procedures have utilized double cages for interbody fusion, but recent studies have shown comparable results and fewer complications with single cages [6]. Over the past decade, PLIF has become a widely adopted technique for arthrodesis in cases of segmental instability of the lumbar spine. When supplemented with additional instrumentation and posterolateral fusion, PLIF has demonstrated high overall fusion rates, ranging from 96% to 100%, with satisfactory clinical outcomes reported in the literature.

Choosing bone graft material for interbody fusion is critical for successful outcomes. While autologous iliac bone graft offers good biological healing ability, it is associated with significant donor site morbidity, including increased operation time, local pain, blood loss, and infection. Alternatively, local lamina bone and facet joint autografts obtained during decompression procedures serve as viable alternatives, offering the advantage of avoiding additional morbidity [7]. Combining lumbar interbody fusion with bone graft and cages, along with decompression of the spinal canal and instrumented posterior stabilization using pedicle screws and rods through a single posterior incision, represents a comprehensive approach to treating spondylolisthesis. This study aims to evaluate the clinical and functional outcomes, fusion rates, structural restoration, and complications associated with this treatment

approach. Through this evaluation, we seek to contribute to the growing body of knowledge on managing spondylolisthesis and inform clinical practice to benefit patients with this condition.

OBJECTIVES

General objective

To evaluate the outcome of Lumbar Interbody Fusion and Posterior Instrumentation in Spondylolisthesis with cage and bone graft.

Specific objectives

To evaluate the clinical outcome after the operation.

To assess the radiological outcome after surgery.

To determine the functional outcome of the patients.

Identify procedure-specific complications.

MATERIAL AND METHODS

Study Design

The study employed a prospective interventional design to assess the outcomes of lumbar interbody fusion and posterior instrumentation in patients diagnosed with spondylolisthesis. This design allowed for the systematic collection of data before and after the surgical intervention, facilitating the evaluation of the treatment's efficacy. The study aimed to provide insights into the clinical, radiological, and functional outcomes following the surgical procedure by prospectively following patients over a defined period. This approach enabled a comprehensive analysis of the effects of the intervention on patients' conditions, contributing to the understanding of optimal management strategies for spondylolisthesis. The prospective nature of the study minimized biases associated with retrospective designs, enhancing the reliability and validity of the findings.

Inclusion Criteria

Symptomatic spondylolisthesis after adequate conservative treatment.

All adult symptomatic patients.

Both male and female.

Progressive neurological deficit.

Exclusion Criteria

Previous spinal surgery in lumbosacral region.

Severe radiological osteoporosis.

It is associated with other spinal pathologies, i.e., spinal tumors, active infections, and auto-immune affection.

Data Collection

Data was collected using a structured questionnaire and a pre-tested data collection sheet. The questionnaire encompassed patient history, clinical examination findings, laboratory investigations, preoperative assessments, perioperative details, and postoperative outcomes. Patients were identified from the emergency or outpatient department

following an X-ray examination and subsequently admitted to the hospital. After counseling and obtaining consent for enrollment, preoperative data were systematically gathered. The operative procedure was performed in consultation with the surgical team, and preoperative and postoperative data were recorded. Patients were followed up for at least 6 weeks, during which clinical, radiological, and functional assessments were conducted. Scores were recorded to evaluate the outcome. This comprehensive approach ensured the systematic collection of relevant data points, facilitating a thorough analysis of the outcomes following lumbar interbody fusion and posterior instrumentation in patients with spondylolisthesis.

Data Analysis

Data analysis was conducted using the Statistical Package for the Social Sciences (SPSS) version 26. Descriptive statistics such as means, standard deviations, frequencies, and percentages were calculated to summarize the demographic and clinical characteristics of the study population. Inferential statistics were employed to assess the associations between variables and outcomes, including chi-square tests or Fisher's exact tests for categorical variables and independent t-tests or Mann-Whitney U tests for continuous variables. Additionally, regression analysis was performed to identify predictors of clinical outcomes, fusion rates, and complications. Statistical significance was set at $p < 0.05$. The rigorous analysis allowed for a comprehensive understanding of the data, identifying significant findings and providing insights into the effectiveness and safety of lumbar interbody fusion and posterior instrumentation in managing spondylolisthesis.

Ethical Consideration

Before this study was commenced, the Ethical committee of Dhaka Medical College approved the research protocol. The aims and objectives of the study were explained to the patients in an easily understandable local language and informed written consent was obtained from each patient. They were also informed about the approximate cost of an MRI of the lumbosacral spine and the instrumentation used. It was ensured that all informed consents and records were kept confidential, and the procedure was helpful for both the doctor and the patients in making a rational approach to case management. The aims and objectives of the study, along with its procedure, alternative diagnostic methods, risks, and benefits, were explained to the patients in an easily understandable local language. Then, informed consent was taken from each patient before being included in the study. It was assured that all records would be kept confidential and that the procedure would be helpful for both the physician and patients make a rational approach regarding the management of lumbar spondylolisthesis. The patient paid the cost of cages, pedicle screws, and rods. No financial support was taken from any organization or patient, and no financial benefit was given to the patient for study.

RESULTS

The study included 21 patients diagnosed with spondylolisthesis, with a mean age of 46.9 years (23-70 years). Of these, 7 (33.3%) were male and 14 (66.7%) were female. Most patients fell within the age range of 41-50 years (28.6%). The distribution of patients by age group is summarized in Table 1.

Table 1: Distribution of Patients by Age Group

Age Group	Number of Patients	Percentage
21-30	2	9.5%
31-40	4	19.0%
41-50	6	28.6%
51-60	7	33.3%
61-70	2	9.5%

The study evaluated the clinical and functional outcomes of lumbar interbody fusion and posterior instrumentation. The mean preoperative Visual Analogue Score (VAS) for back pain was 6.83 ± 0.49 , and for leg pain was

6.75 ± 0.60 . Postoperatively, there was a significant improvement in both back pain (2.27 ± 0.57) and leg pain (1.28 ± 0.46), with p-values < 0.001 for both variables (Table 2).

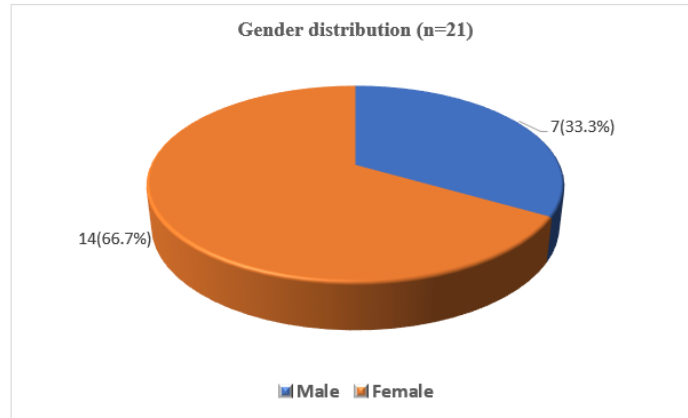


Figure 1: Pie chart showing the gender distribution of the study patients (n=21)

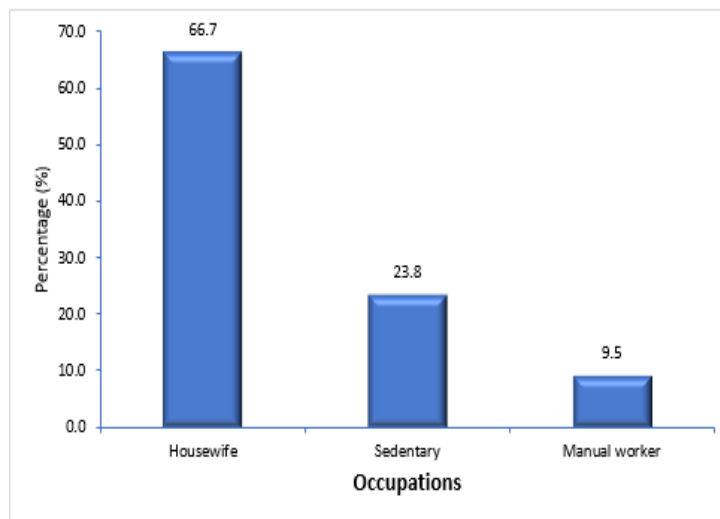


Figure 2: Bar diagram showing the occupation distribution of study patients

Among occupational distribution, homemakers comprised the main bulk, 66.7%. Other occupants were sedentary, 23.8%, and manual workers, 9.5%.

Table 2: Distribution of the study patients by Level of Listhesis (n=21)

Level of injury	Number of patients	Percentage (%)
L 4 over L 5	17	81.0
L 5 over S 1	4	19.0
Total	21	100

In this series, the most involved L4 over L5 level was 17 (81.0%).

Table 3: Type of Spondylolisthesis (n=21)

Type of Spondylolisthesis	Number of patients	Percentage (%)
Lytic	12	57.1
Degenerative	8	38.1
Dysplastic	1	4.8
Total	21	100.0

Among 21 study subjects, 57.1% of patients had lytic, 38.1% of patients had degenerative, and 4.8% of patients had dysplastic type of spondylolisthesis.

Table 4: Grade of Spondylolisthesis (n=21)

Grade	Number of patients	Percentage (%)
I	6	28.6
II	15	71.4
Total	21	100

Among 21 patients in this series, grade II slippage was 15 (71.4%), followed by grade I 6(28.6%).

Table 5: Postoperative complications (n=21)

Postoperative complication	Number of patients	Percentage (%)
No complication	19	90.5
Superficial surgery site infection	2	9.5
Pseudarthrosis	0	0.0
Implant failure	0	0.0
Total	21	100.0

In this series, 2(9.5%) patients had superficial surgical site infection and one pseudomonas managed by antibiotics. According to the C/S report, one patient had *e.coli*

Table 6: Comparison of ODI preoperative and postoperative (n=21)

	Preoperative (n=21)	Postoperative (n=21)	p-value
ODI	57.78±2.25	16.56±3.53	<0.001*

Data were expressed as mean±SD

P value reached from the paired t-test, * = significant

The comparison of preoperative and postoperative ODI. Mean preoperative ODI 57.78±2.25 and postoperative ODI 16.56±3.53. The mean difference between preoperative and postoperative ODI was statistically significant.

Table 7: Comparison of motor function assessed by MRC grading preoperative and postoperative (n=21)

Motor deficit	Number of patients	Percentage (%)
Preoperative		
MRC grading reduced	11	52.4
Normal	10	47.6
Postoperative		
MRC grading reduced	2	9.5
Normal	19	90.5

Pre-operatively, 11(52.4%) patients had motor deficits (assessed clinically according to MRC grading). After six months of operation, it reduced to 2 (9.5%).

Table 8: Functional Outcome of the study measured by Macnab criteria (n=21)

Macnab criteria	Number of patients	Percentage (%)
Excellent	17	81.0
Good	4	19.0
Fair	0	0
Poor	0	0
Total	21	100

Regarding the modified Macnab criteria of the study patients, 17(81.0%) were excellent in the final follow-up, and only 4(19.0%) were good.

DISCUSSION

In present study, out of 21 patients, 2(9.5%) was 21-30 years old, 4(19.0%) was 31-40 years old, 6(28.6%) was 41-

50 years old, 7(33.3%) was 51-60 years old and 2(9.5%) was 61-70 years old. The mean age was 46.9±13.7 years, and the lowest and highest ages were 23 and 70, respectively. Males were found in 7(33.3%) cases, and females were found in

14(66.7%) cases. As reported in a related study, the mean age was 56.6 years, with 06 males and 22 females. In this study, the posterior lumbo sacral interbody fusion with cages and bone graft with instrumentation technique in the treatment of spondylolisthesis resulted in significant clinical and functional improvement, structural restoration, fusion, and stability had been associated with low rates of intraoperative neural complications [8]. In this series, improvement of pain status measured by Visual Analogue Score (VAS) is back pain improvement from (6.83±0.49 to 2.27±0.57) and leg pain improvement from (6.75±0.60 to 01.28±0.46), p-value of both of which is 0.001 which is statistically significant. In the initial series, the improvement of VAS score of back pain was (07.18 ± 01.09 to 01.84 ± 0.91) and leg pain improvement was (06.88 ± 01.21 to 01.34 ± 0.97) both of which is comparable to this study. In this series, improvement of disability measured by the Oswestry Disability Index (ODI) is (57.78±02.25 to 16.56± 3.53) after 6 months of follow-up; here, the p-value is 0.0001, which is statistically significant in the study of [9,10]. It was shown that, in 54 patient series, the Oswestry Disability Index (ODI %) was 60.00 ± 01.21 pre-operatively and 17.09± 0.97 after 6 months of follow-up, comparable to this study.

An excellent outcome was observed in around 92.86% of posterior lumbar interbody fusion cases using Macnab criteria. This was also comparable to this study, where 14(78%) were excellent in the final follow-up, and only 4(22%) were found to be good. The development of pseudoarthrosis is one of the most common complications of interbody fusion (range, 05-45%). In this study, we achieved a 100% fusion rate using Hackenberg criteria, comparable to where pseudoarthrosis was present in two (2.60%) patients in their series [11]. Regarding complications, 9.5% of the patients developed minor complications in current series such as superficial infection managed by regular dressing and oral antibiotics. He reported 6.6% of infection in his study on posterior lumbo sacral interbody fusion group and reported that the wound complications rate was 0.6% to 5%, comparable with our result [12]. The criteria used to analyze the overall outcome were proposed by Modified Macnab criteria, which are based on relief of back and leg pain, return of employment, restriction of physical activities, and use of analgesics for lumbar spine fusion. In this series, 17 patients (81.0%) got excellent results, and 4(19.0%) got good results. In agreement with this, this study reported the excellent outcome in 69 patients (84%), fair result was seen in 4(5%), good in 5 (6%) & poor results in 4 (5%) cases [13]. They measured the clinical outcome using the Oswestry disability index. 35 (87.5%) patients had excellent and good outcomes, which was almost the same when compared to the study of (90%) and slightly more than (81%) [14]. We got 85.3% excellent and good results with satisfactory clinical outcomes comparable to ours. To conclude, the Posterior Lumbosacral Interbody fusion method effectively relieves symptoms, achieves stability and fusion, and reduces complication rates in the surgical management of spondylolisthesis [15-18].

CONCLUSION

This study may conclude that lumbar interbody fusion, decompression and posterior instrumentation is an effective procedure for treating spondylolisthesis. Though surgical procedures cannot confirm lifelong recovery of the patients with symptoms, they do ensure a better and more comfortable lifestyle with the potential improvement of leg symptoms in case of degenerative spondylolisthesis. A better outcome will be ensured despite successful fusion if any activity that may overload the back is avoided. This method enhances symptoms, reduces pain, and efficiently improves functional outcomes.

Recommendation

The study should be repeated with a large sample size for all practical purposes.

It should be conducted with long-term follow-up.

More multicenter studies are needed to clarify the findings.

Should be available C-Arm related OT.

Acknowledgments

I gratefully acknowledge the support and guidance of Almighty Allah for granting me the strength to pursue this research. Special thanks to my supervisor, Prof. Dr. Md. Shah Alam, and esteemed faculty members, Prof. Dr. Md. Fakrul Amin Khan, Prof. Dr. Md. Saidul Islam, Prof. Dr. Md. Golam Sarwar, Assoc. Prof. Dr. Mohammad Khurshed Alam and Dr. Md. Shahidul Islam Akon. I also thank my colleagues, hospital staff, and patients for cooperating. I greatly appreciate my parents, spouse, Dr. Faria Jebin, and daughters Fairuzah Rahman and Nusaiba Rahman for their unwavering support. May Allah bless all involved.

Article at a glance

Study purpose: Evaluate outcomes of lumbar interbody fusion in spondylolisthesis.

Key findings: High fusion rates (81%), significant improvement in Oswestry Disability Index scores (from 57.78±2.25 to 16.56±3.53), excellent outcomes in 81% of cases.

Newer findings: PLIF with single cages showed comparable results and fewer complications, contributing to the understanding of optimal surgical approaches.

Funding: No funding sources

Conflict of interest: None declared

REFERENCES

1. Rakesh, S. (2014). *A Prospective study of short term clinical and radiological analysis of lumbar interbody fusion for degenerative disc disease and spondylolisthesis* (Doctoral dissertation, Kilpauk Medical College, Chennai).

2. García-Ramos, C. L., Valenzuela-González, J., Baeza-Álvarez, V. B., Rosales-Olivarez, L. M., Alpizar-Aguirre, A., & Reyes-Sánchez, A. (2021). Degenerative spondylolisthesis I: general principles. *Acta ortopédica mexicana*, 34(5), 324-328.
3. Aoki, Y., Takahashi, H., Nakajima, A., Kubota, G., Watanabe, A., Nakajima, T., ... & Ohtori, S. (2020). Prevalence of lumbar spondylolysis and spondylolisthesis in patients with degenerative spinal disease. *Scientific Reports*, 10(1), 6739.
4. Hegde, D., Mehra, S., Babu, S., & Ballal, A. (2017). A study to assess the functional outcome of decompression and posterior lumbar interbody fusion of low grade spondylolisthesis of lumbar vertebra. *Journal of Clinical and Diagnostic Research: JCDR*, 11(3), RC01.
5. Litak, J., Czyzewski, W., Szymoniuk, M., Pastuszek, B., Litak, J., Litak, G., ... & Kamieniak, P. (2022). Hydroxyapatite use in spine surgery—molecular and clinical aspect. *Materials*, 15(8), 2906.
6. Vivek, K. (2020). *Functional Outcome following Pedicle Screw Instrumentation and Fusion for Low Grade Lumbar Spinal Instability in Tertiary Care Hospital, Kanchipuram District* (Doctoral dissertation, Karpaga Vinayaga Institute of Medical Sciences and Research Centre, Kanchipuram).
7. Liu, J., Deng, H., Long, X., Chen, X., Xu, R., & Liu, Z. (2016). A comparative study of perioperative complications between transforaminal versus posterior lumbar interbody fusion in degenerative lumbar spondylolisthesis. *European Spine Journal*, 25, 1575-1580.
8. Alam, M. S., Karim, M. R., Islam, S. S., Roy, U. K., Sabuj, S. H., Alam, M., ... & Khan, K. M. H. Results of Posterior Interbody Fusion and Transpedicular Screws Fixation for the Treatment of Spondylolisthesis. *The Journal of Bangladesh Orthopaedic Society (JBOS)*, 90.
9. Lin, Y., Chen, W., Chen, A., & Li, F. (2016). Comparison between minimally invasive and open transforaminal lumbar interbody fusion: a meta-analysis of clinical results and safety outcomes. *Journal of Neurological Surgery Part A: Central European Neurosurgery*, 77(01), 002-010.
10. Hossain, Q., Hossain, A., Nizum, M. Z., & Naser, S. B. (2024). Influence of Artificial Intelligence on Customer Relationship Management (CRM). *International Journal of Communication Networks and Information Security*, 16(3), 653-663.
11. Saravanakumar, R., Maniraj, S. P., Barshan, A. D., Das, S., Hasan, H., & Alazzam, M. B. (2023, November). Clustering big data for novel health care system. In AIP Conference Proceedings (Vol. 2587, No. 1). AIP Publishing.
12. Khan, M. S., Rayhan, M. F., Harun, M. E., Rahaman, M. S., Naher, K., Khan, M. T., & Hasan, S. Z. (2023). Functional & Clinical Outcomes of Posterior Decompression & Transforaminal Lumbar Interbody Fusion (TLIF) Using Cage and Bone Graft Combined with Stabilization in Lumbar Spondylolisthesis. *Sch J App Med Sci*, 9, 1723-1729.
13. Tye, E. Y., Tanenbaum, J. E., Alonso, A. S., Xiao, R., Steinmetz, M. P., Mroz, T. E., & Savage, J. W. (2018). Circumferential fusion: a comparative analysis between anterior lumbar interbody fusion with posterior pedicle screw fixation and transforaminal lumbar interbody fusion for L5–S1 isthmic spondylolisthesis. *The Spine Journal*, 18(3), 464-471.
14. Amin, M. R., Rahman, M. A., Khan, A. H., Devnath, H., Hossain, A. M., Hasan, M., & Barua, K. K. (2017). Posterior lumbar interbody fusion with pedicle screw fixation for the management of spondylolisthesis: An analysis of 40 cases. *Age (Years)*, 21(30), 2.
15. Macki, M., Bydon, M., Weingart, R., Sciubba, D., Wolinsky, J. P., Gokaslan, Z. L., ... & Witham, T. (2015). Posterolateral fusion with interbody for lumbar spondylolisthesis is associated with less repeat surgery than posterolateral fusion alone. *Clinical neurology and neurosurgery*, 138, 117-123.
16. Hussain, M. D., Rahman, M. H., & Ali, N. M. (2024). Investigation of Gauss-Seidel Method for Load Flow Analysis in Smart Grids. *Sch J Eng Tech*, 5, 169-178.
17. Hasan, H., Rahman, M. H. ., Haque, M. A., Rahman, M. S. ., Ali, M. S. ., & Sultana, S. . (2024). Nutritional Management in Patients with Chronic Kidney Disease: A Focus on Renal Diet. *Asia Pacific Journal of Medical Innovations*, 1(1), 34-40.
18. Lara-Almunia, M., Gomez-Moreta, J. A., & Hernandez-Vicente, J. (2015). Posterior lumbar interbody fusion with instrumented posterolateral fusion in adult spondylolisthesis: description and association of clinico-surgical variables with prognosis in a series of 36 cases. *International Journal of Spine Surgery*, 9.