

ARTICLE



The Diagnostic Value of Fine Needle Aspiration Cytology in Pediatric Cervical Lymphadenopathy

Sk. Md. Abdur Razzaque^{1*}, Towhidul Islam², A.K.M Mizanur Rahman², Nazmun Naher Poly³, Diponkar Kumar saha⁴

¹ Resident Surgeon, Department of Pediatric Surgery, Sher-E-Bangla Medical Collage Hospital, Barisal

² Associate Professor, Department of Pediatric Surgery, Sher-E-Bangla Medical Collage Hospital, Barisal

³ Registrar, Department of Gynae & Obs, TMSS Medical College & Rafatullah Community Hospital, Bogura

⁴ Assistant Professor, Department of Pediatric Surgery, Sher-E-Bangla Medical Collage Hospital, Barisal

ABSTRACT

Background: Cervical lymphadenopathy is a common condition in pediatric patients, and early diagnosis is crucial for appropriate treatment. Fine Needle Aspiration Cytology (FNAC) is a valuable diagnostic tool. **Objective:** This study aimed to assess the accuracy and usefulness of FNAC in diagnosing pediatric cervical lymphadenopathy in patients under 12 years of age. **Method:** A prospective study was conducted at Sher-E-Bangla Medical College Hospital from November 2022 to February 2024. A total of 45 pediatric patients with cervical lymphadenopathy underwent FNAC followed by lymph node excision biopsy. FNAC results were compared with histopathological findings to evaluate the diagnostic accuracy. **Results:** Out of 45 patients, FNAC diagnosed 34 (75.55%) reactive hyperplasia, 2 (4.44%) tubercular granuloma, 1 (2.22%) non-tubercular granuloma, 2 (4.44%) pyogenic, 1 (2.22%) Hodgkin's lymphoma, 3 (6.66%) non-Hodgkin's lymphoma, 1 (2.22%) suspicious of malignancy, and 1 (2.22%) unsatisfactory for malignancy. The histopathological assessment confirmed 1 reactive lymph node as malignant (false negative), with no false positives. The sensitivity for benign conditions was 97.56%, specificity was 100%, positive predictive value was 100%, negative predictive value was 66.66%, and overall diagnostic accuracy was 97.67%. **Conclusions:** FNAC is a highly accurate and useful tool for diagnosing pediatric cervical lymphadenopathy and should be included in the initial diagnostic process before determining the treatment plan.

Keywords: Pediatric, Lymphadenopathy, FNAC, Histopathology, Diagnosis

| **Submitted:** 11.09.2024 | **Accepted:** 15.09.2024 | **Published:** 18.09.2024

*Corresponding Author

Sk. Md. Abdur Razzaque, Resident Surgeon, Department of Pediatric Surgery, Sher-E-Bangla Medical Collage Hospital, Barisal
Email: razzaqueopd7@gmail.com

How to Cite the Article

Sk. Md. Abdur Razzaque, Towhidul Islam, A.K.M Mizanur Rahman, Nazmun Naher Poly, Diponkar Kumar saha: The Diagnostic Value of Fine Needle Aspiration Cytology in Pediatric Cervical Lymphadenopathy. *IARJ. Med & Surg Res.* 2024;5(5): 1-8.

© 2024 IAR Journal of Medicine and Surgery Research, a publication of JMSRP Publisher, Kenya.

This is an open access article under the terms of the Creative Commons Attribution license.

(<http://creativecommons.org/licenses/by/4.0>).

(<https://jmsrp.or.ke/index.php/jmsrp>).

INTRODUCTION

Lymph node fine needle aspiration cytology (FNAC) has proven a highly effective diagnostic tool, particularly in the pediatric population [1]. This minimally invasive technique provides a reliable and accurate method for evaluating pediatric lymphadenopathy, which is critical in determining the underlying cause of lymph node enlargement.

FNAC is favored in clinical practice due to its minimal complications and high diagnostic yield, particularly when performed by experienced cytopathologists. It has demonstrated significant sensitivity and specificity in detecting various pathologies, ranging from benign inflammatory conditions to malignant diseases, making it an essential component in managing pediatric lymphadenopathy

[2]. Lymph node enlargement is a common clinical presentation in the pediatric population and can result from numerous etiologies, including infectious, inflammatory, and malignant processes. Although the majority of enlarged lymph nodes in children are due to benign conditions, it is crucial to differentiate these from more serious pathologies. Lymph nodes with a short axis greater than 10 mm are generally considered abnormal, with exceptions for deep cervical lymph nodes where a diameter of up to 15 mm is considered within normal limits [3]. Clinicians typically decide to remove lymph nodes when the diameter exceeds 2 cm, or even smaller in certain locations, such as the supraclavicular, epitrochlear, popliteal, and preauricular regions, where malignancies are more likely to occur. Additionally, lymph nodes that exhibit changes in form, consistency, or mobility, or those that persist for longer than 2-4 weeks, often raise suspicion for malignancy. These clinical findings and associated symptoms, such as fever, night sweats, or weight loss, may prompt further evaluation [4,5].

Palpable supraclavicular lymph nodes, in particular, are always considered abnormal in pediatric patients due to their strong association with malignancies. Furthermore, enlarged lymph nodes in two or more non-contiguous regions, termed generalized lymphadenopathy, often indicate systemic infections or malignancies and warrant a comprehensive workup [6]. Cervical lymphadenopathy is the most common form of lymph node enlargement in children and is predominantly caused by benign conditions such as reactive hyperplasia, which accounts for approximately 85% of cases. Reactive hyperplasia, or nonspecific lymphadenitis, is often the result of viral or bacterial infections [7]. However, other serious causes, including Hodgkin's lymphoma, non-Hodgkin's lymphoma, metastatic lymphadenitis, and granulomatous lymphadenitis (such as tubercular or foreign body granulomas), may also present with cervical lymphadenopathy [8,9]. The use of FNAC is particularly valuable in this clinical context, as it allows for the rapid and accurate assessment of lymph node pathology without the need for more invasive procedures, such as excision biopsy. FNAC has emerged as an important tool in the diagnostic workup of pediatric lymphadenopathy, as it can help predict which patients are more likely to benefit from a biopsy. In cases where FNAC suggests benign reactive changes, it may be possible to avoid unnecessary surgeries, while a diagnosis of malignancy or granulomatous disease on FNAC would prompt a more aggressive workup [10].

Studies have demonstrated that FNAC has high diagnostic accuracy and, sensitivity and specificity rates, making it a valuable adjunct to clinical evaluation [11,12]. The accuracy of FNAC is especially crucial in pediatric patients, where minimizing invasive procedures and reducing anxiety is a priority. Given its advantages, FNAC has increasingly become essential to the initial diagnostic evaluation of pediatric cervical lymphadenopathy. This study aimed to evaluate the

usefulness and accuracy of FNAC in diagnosing pediatric cervical lymphadenopathy by comparing FNAC results with histopathological findings. By doing so, we sought to determine whether FNAC should be routinely incorporated into the initial diagnostic workup for pediatric patients presenting with cervical lymphadenopathy. The findings from this study may further establish FNAC as a critical diagnostic tool in this context, improving patient care and outcomes.

Aims and Objective

This study aimed to assess the accuracy and effectiveness of fine needle aspiration cytology (FNAC) in diagnosing cervical lymphadenopathy in pediatric patients. Specifically, the study sought to reduce the need for excisional biopsies, minimize surgical risks, and lower diagnostic costs, ensuring safer and more efficient patient care.

MATERIAL AND METHODS

Study Design

This prospective, observational study was conducted at the Pediatric Surgery Department of Sher-E-Bangla Medical College Hospital, Barisal, from November 2022 to February 2024. A total of 45 pediatric patients, aged between 5 and 12 years, with cervical lymphadenopathy, were included based on defined inclusion and exclusion criteria. FNAC was performed on all patients, followed by an excisional biopsy. The FNAC results were compared with histopathological findings to evaluate the diagnostic accuracy of the procedure.

Inclusion Criteria

The study included pediatric patients aged 5 to 12 years presenting with cervical lymphadenopathy that persisted for 2 to 4 weeks. Lymph nodes larger than 1 cm in diameter were considered for evaluation, emphasizing nodes that showed changes in size, consistency, or mobility over time. Only those cases where the clinical presentation necessitated further investigation, as determined by pediatric surgeons, were included in the study to assess FNAC's diagnostic accuracy.

Exclusion Criteria

Patients were excluded if they exhibited signs of systemic infection, such as fever or septicemia, or were malnourished. Children with bleeding disorders, such as hemophilia, were also excluded due to the increased risk of complications during FNAC. Additionally, patients with psychiatric disorders or those unfit for general or local anesthesia were not considered for this study to ensure patient safety during the diagnostic procedures.

Data Collection

Data were collected prospectively from 45 pediatric patients who presented with cervical lymphadenopathy at Sher-E-Bangla Medical College Hospital from November 2022 to February 2024. Demographic information, clinical

history, and physical examination findings were recorded. Fine needle aspiration cytology (FNAC) was performed, and the results were compared with subsequent histopathological diagnoses from excisional biopsies. Ultrasound findings of the lymph nodes were also noted. All data were documented systematically to evaluate the diagnostic accuracy and effectiveness of FNAC in this patient population.

Data Analysis

Data analysis was conducted using SPSS version 26. Descriptive statistics, such as frequencies and percentages, were used to summarize demographic data and the distribution of FNAC and histopathological findings. Sensitivity, specificity, positive predictive value (PPV), negative predictive value (NPV), and overall diagnostic accuracy were calculated to assess the performance of FNAC in comparison to histopathology. The chi-square test was employed to determine the significance of the association between FNAC and histopathological diagnoses. A p-value of less than 0.05 was considered statistically significant, and all results were presented with 95% confidence intervals.

Ethical Considerations

Ethical approval for the study was obtained from the Institutional Review Board (IRB) of Sher-E-Bangla Medical College Hospital, ensuring adherence to ethical guidelines. Informed consent was obtained from the parents or guardians of all pediatric patients before participation. The study ensured confidentiality, and all patient data were anonymized. The procedures, including FNAC and excisional biopsy, were performed with minimal risk to the patients, and their safety and well-being were prioritized throughout the research process.

RESULTS

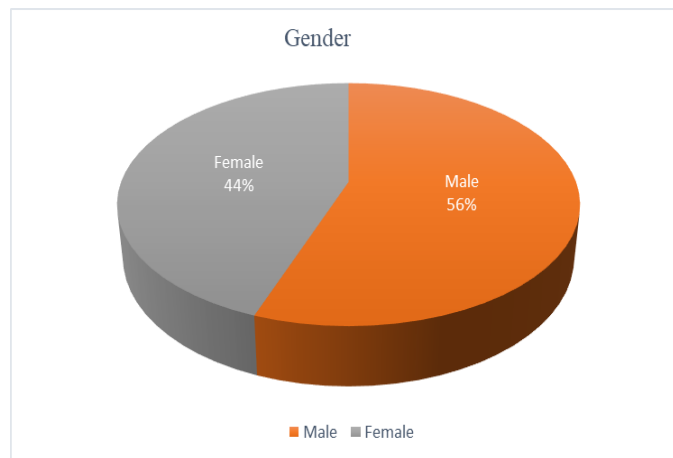
This study included 45 pediatric patients aged 5 to 12 years who presented with cervical lymphadenopathy. FNAC was performed on all patients, followed by histopathological examination to compare the accuracy of FNAC in diagnosing lymphadenopathy.

Table 1: Demographic Characteristics

Characteristics	Number of Patients (N=45)	Percentage (%)
Age Group		
5-8 years	20	44.44%
9-12 years	25	55.56%
Gender		
Male	25	55.56%
Female	20	44.44%
Duration of Lymphadenopathy		
2-4 weeks	35	77.78%
More than 4 weeks	10	22.22%

Figure 1: Distribution of patients according to Sex

Table 1 shows that most patients (55.56%) were 9-12 years old (44.44%). Most patients (77.78%) presented with



years old, with slightly fewer (44.44%) in the 5-8 years group. Males constituted a higher proportion (55.56%) than females

lymphadenopathy lasting 2-4 weeks, while 22.22% experienced symptoms for more than 4 weeks, indicating the

need for prompt diagnostic evaluation in persistent cases.

Table 2: FNAC Diagnosis of Pediatric Cervical Lymphadenopathy

FNAC Diagnosis	Number of Patients (N=45)	Percentage (%)
Reactive Hyperplasia	34	75.55%
Tubercular Granuloma	2	4.44%
Non-Tubercular Granuloma	1	2.22%
Pyogenic	4	8.88%
Hodgkin's Lymphoma	1	2.22%
Non-Hodgkin's Lymphoma	1	2.22%
Suspicious of Malignancy	1	2.22%
Unsatisfactory	1	2.22%

The FNAC results reveal that the majority of cases (75.55%) were diagnosed as reactive hyperplasia, indicating a benign condition. Tubercular granuloma and non-tubercular granuloma accounted for 4.44% and 2.22% of cases, respectively. Pyogenic lymphadenopathy was seen in 8.88%

of patients. Malignancies, such as Hodgkin's and Non-Hodgkin's lymphoma, each comprised 2.22% of cases. Additionally, 2.22% of the samples were suspicious of malignancy, and 2.22% were deemed unsatisfactory, underscoring the importance of follow-up in certain cases.

Table 3: Histopathological Results

Histopathological Diagnosis	Number of Patients (N=45)	Percentage (%)
Reactive Hyperplasia	33	73.33%
Tubercular Granuloma	2	4.44%
Non-Tubercular Granuloma	1	2.22%
Pyogenic	4	8.88%
Hodgkin's Lymphoma	1	2.22%
Non-Hodgkin's Lymphoma	4	8.88%

The histopathological results closely align with the FNAC findings. The majority of cases (73.33%) were diagnosed as reactive hyperplasia, consistent with benign conditions. Tubercular granuloma and non-tubercular granuloma were confirmed in 4.44% and 2.22% of cases,

respectively. Pyogenic lymphadenopathy was identified in 8.88% of patients. Hodgkin's lymphoma accounted for 2.22%, while a higher incidence of non-Hodgkin's lymphoma (8.88%) was confirmed histologically, indicating its importance in diagnosing pediatric cervical lymphadenopathy.

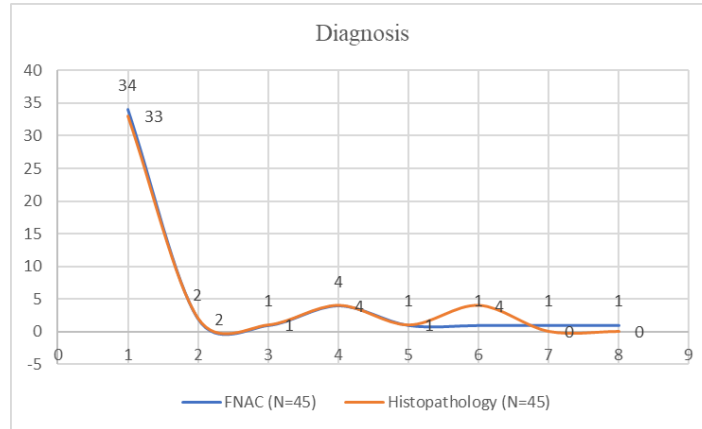


Figure 2: Comparison of FNAC and Histopathological Diagnosis

The comparison between FNAC and histopathological diagnoses reveals a high level of agreement between the two methods. For reactive hyperplasia, FNAC identified 34 cases, while histopathology confirmed 33. Both methods agreed on the diagnoses of tubercular granuloma, non-tubercular granuloma, pyogenic, and Hodgkin’s lymphoma. However, FNAC identified only one case of non-

Hodgkin’s lymphoma, whereas histopathology confirmed four cases, highlighting FNAC’s limitations in some malignancies. Additionally, FNAC categorized one case as suspicious of malignancy and one as unsatisfactory, which were not confirmed by histopathology, indicating possible misdiagnoses or inadequate samples.

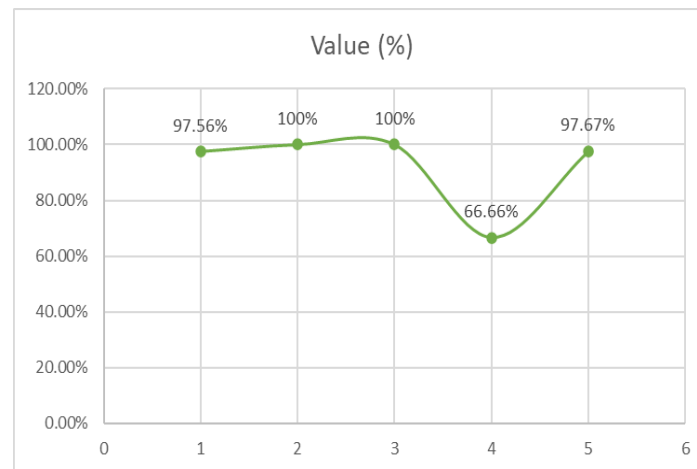


Figure 3: Diagnostic Accuracy of FNAC

The FNAC demonstrated high diagnostic accuracy with a sensitivity of 97.56% for benign cases, 100% specificity for malignancy, 100% positive predictive value, 66.66% negative predictive value, and overall accuracy of 97.67%.

DISCUSSION

The present study aimed to assess the diagnostic accuracy and utility of fine needle aspiration cytology (FNAC) in pediatric cervical lymphadenopathy, specifically in children aged 5 to 12 years. Our findings demonstrate that FNAC is a highly sensitive and specific diagnostic tool, with an overall diagnostic accuracy of 97.67%. These results align with prior studies that underscore the reliability of FNAC in distinguishing between benign and malignant causes of

lymphadenopathy in children [13,14]. The high specificity and positive predictive value (100%) indicate that FNAC can effectively rule out malignancy in pediatric cases, thus reducing the need for more invasive diagnostic procedures like excisional biopsy. However, a lower negative predictive value (66.66%) suggests that, although rare, some malignant cases may be misdiagnosed as benign, warranting careful clinical correlation and follow-up [15]. Our study’s findings are consistent with several studies that highlight the role of FNAC as a first-line diagnostic tool in evaluating cervical lymphadenopathy. A study by Raina *et al.*, reported an FNAC sensitivity of 94%, slightly lower than our study’s sensitivity of 97.56% but still within an acceptable range [16]. This difference in sensitivity could be attributed to the sample size

and the inclusion of a broader age range in the Shakeri *et al.* study, which included both adults and children, potentially affecting the diagnostic performance of FNAC. Similar results were found in a study by Ronchi *et al.*, where the authors reported a diagnostic accuracy of 96%, closely matching our findings [17]. The slight variation in diagnostic accuracy could be attributed to differences in sample size and patient demographics, such as geographic location and the prevalence of tuberculosis, which is more common in certain populations and might affect lymphadenopathy presentation.

In contrast, a study conducted in a Brazilian population by Sellami *et al.*, reported a sensitivity of 87% and a specificity of 95% for FNAC, figures that are lower than those observed in our study [18]. This discrepancy may be due to differences in the epidemiological profiles of the populations studied. In regions with a higher prevalence of infectious diseases such as tuberculosis or HIV, lymphadenopathy may present with more complex cytological features, potentially affecting FNAC accuracy. Moreover, racial and genetic differences between populations could play a role in lymph node pathology, as lymphadenopathy may have different etiologies depending on geographic and ethnic backgrounds [19]. The results of this study have several important clinical and practical implications. First, the high diagnostic accuracy of FNAC reinforces its value as a minimally invasive, cost-effective, and safe diagnostic tool in the pediatric population. In resource-limited settings, where access to surgical facilities may be constrained, FNAC offers an efficient alternative to excisional biopsy for diagnosing cervical lymphadenopathy. As observed in our study, the minimal complications associated with FNAC further emphasize its practical significance. Only two patients reported mild discomfort, which resolved without intervention, indicating that FNAC is a well-tolerated procedure in children. This finding supports the routine use of FNAC as a first-line investigation in pediatric patients presenting with lymphadenopathy, especially when considering the risks associated with general anesthesia and surgical excision in young children.

Second, the research findings suggest that FNAC may help reduce the need for unnecessary surgical interventions. In our study, 34 of the 45 cases (75.55%) were diagnosed with reactive hyperplasia, a benign condition that often resolves without treatment. The ability of FNAC to accurately diagnose these benign cases means that children can be spared from more invasive procedures like biopsy, which not only carry risks of complications but also incur higher healthcare costs. Furthermore, using FNAC could reduce the burden on healthcare systems by streamlining the diagnostic process and enabling quicker treatment decisions. However, the study also highlights the importance of recognizing the limitations of FNAC. Although FNAC is highly specific for malignancy, with no false positives observed in our study, one false negative case emphasizes the

need for caution when interpreting benign FNAC results in the presence of clinical suspicion for malignancy. This finding underscores the necessity of integrating FNAC results with clinical and radiological findings to avoid misdiagnosis and ensure that patients with malignancies receive timely and appropriate treatment. For example, in cases where clinical findings suggest malignancy but FNAC results are benign, clinicians should consider follow-up FNAC, core needle biopsy, or excisional biopsy to confirm the diagnosis [20].

Several factors may explain the differences between our findings and those of other studies. One potential reason is the difference in sample size. Studies with larger sample sizes, such as those conducted by Chaurasia *et al.*, tend to report slightly lower sensitivity and specificity values due to the inclusion of a wider variety of cases, including those with atypical or difficult-to-diagnose lymphadenopathy [21]. In contrast, smaller studies like ours, which focused specifically on pediatric cervical lymphadenopathy, may yield higher diagnostic accuracy due to a more homogeneous study population and more controlled diagnostic procedures. Another important factor to consider is the geographic origin of the patient population. Our study was conducted in Barisal, Bangladesh, where tuberculosis and other granulomatous diseases are more prevalent than in Western countries [22]. This higher prevalence of infectious diseases may influence the cytological patterns seen in FNAC, potentially leading to more reactive hyperplasia and granulomatous lymphadenitis cases, which are easier to diagnose cytologically. In contrast, studies conducted in regions with lower rates of infectious diseases may encounter more cases of lymphadenopathy caused by malignancies or autoimmune conditions, which may be more challenging to diagnose with FNAC alone. Racial and genetic differences between populations may also contribute to variations in study findings. Certain racial groups may have different susceptibilities to particular diseases, such as lymphoma or tuberculosis, which can influence the diagnostic performance of FNAC [23-25]. For example, the incidence of Hodgkin's lymphoma varies significantly between populations, with higher rates observed in Western countries compared to Asian countries. This variation may affect the diagnostic sensitivity of FNAC in different regions, as the cytological features of lymphadenopathy may vary depending on the underlying pathology.

The practical significance of our findings is substantial, particularly in low-resource settings. FNAC is a simple and cost-effective procedure performed in outpatient settings without general anesthesia. Its ability to accurately diagnose benign conditions, such as reactive hyperplasia, means that it can be used as a screening tool to rule out malignancy in children presenting with lymphadenopathy, thus reducing the need for unnecessary biopsies and surgeries. The high specificity of FNAC also means that when malignancy is suspected, clinicians can be confident in the diagnosis and proceed with further treatment planning without

delay. Moreover, FNAC's role in reducing healthcare costs cannot be understated. By providing a quick and reliable diagnosis, FNAC can help avoid the costs associated with surgical interventions, including hospitalization, operating room time, and post-operative care. In addition, because FNAC can be performed in an outpatient setting, it reduces the need for hospital admissions, freeing up valuable healthcare resources for more critically ill patients. FNAC is a highly effective diagnostic tool for evaluating pediatric cervical lymphadenopathy, offering high sensitivity, specificity, and diagnostic accuracy. Its ability to accurately distinguish between benign and malignant conditions, its minimally invasive nature, and its cost-effectiveness make it a valuable tool in pediatric surgical practice. However, clinicians should remain cautious when interpreting FNAC results, particularly in cases where clinical suspicion of malignancy remains high. Further research with larger sample sizes and diverse populations would be beneficial to confirm the findings of this study and further explore the role of FNAC in different geographic and clinical settings.

CONCLUSION

Fine needle aspiration cytology (FNAC) is a highly accurate, minimally invasive, and cost-effective diagnostic tool for pediatric cervical lymphadenopathy. With its high sensitivity and specificity, FNAC helps reduce the need for excisional biopsies and lowers healthcare costs. However, careful clinical correlation is necessary, especially in suspicious clinical findings.

Recommendations

FNAC should be the first-line diagnostic tool for pediatric cervical lymphadenopathy. Regular follow-up is necessary when clinical suspicion persists despite benign FNAC results. Further studies with larger populations are recommended to validate these findings.

Acknowledgment

We would like to express our sincere gratitude to the Department of Pediatric Surgery at Sher-E-Bangla Medical College Hospital for their support and guidance throughout the study. Special thanks to all the pathologists and pediatric surgeons who contributed their expertise and time, as well as to the patients and their families for their cooperation, making this study possible. Without their support, this research would not have been successful.

Funding: No funding sources

Conflict of interest: None declared

REFERENCES

- Awasthi, P., Rai, T., Rai, G. S., Uniya, U., & Gurjar, R. (2019). Age and gender wise distribution of cases presenting with cervical lymphadenopathy: A retrospective study. *Indian J Pathol Oncol*, 6(1), 141-5.
- Jhaveri, S. A. (2019). Spectrum of Pathologies on Fine Needle Aspiration Cytology Evaluation of Peripheral Lymph Nodes at Tertiary Care Center in SMIMER, Surat: A Retrospective Study. *National Journal of Medical Research*, 9(04), 154-158.
- Sharma, N., Singh, M., Sharma, P., Nahar, R., & Goyal, V. P. (2020). Clinical profile of cervical lymphadenopathy and to find diagnostic efficacy of fine-needle aspiration cytology, ultrasonography and histopathological examination. *Int J Otorhinolaryngol Head Neck Surg*, 6, 551.
- Panel, O. T. (2020). 32 nd Congress of the ESP and XXXIII International Congress of the IAP. *Virchows Archiv*, 477(1), S1-S390.
- Chaurasia, R. K., & Sharma, P. (2019). A cytological study of pattern of lymph node lesions at tertiary care centre in Uttar Pradesh. *Int J Res Rev*, 6(12), 568-73.
- Joshi, B. (2021). Study of Fine Needle Aspiration Cytology of Lymph Nodes: A Retrospective Analysis. *Post-Graduate Medical Journal of NAMS*, 21(1), 45-53.
- Hashmi, A. A., Naz, S., Ahmed, O., Yaqeen, S. R., Irfan, M., Kamal, A., & Faridi, N. (2020). Utility of fine needle aspiration cytology in the evaluation of lymphadenopathy. *Cureus*, 12(12).
- Shiladaria, P. B., & Khant, V. S. Role of FNAC in evaluation and diagnosis of head and neck lesions: A retrospective study at tertiary care center.
- Hogan, K. M., Lagoo, A. S., & Inamdar, K. V. (2020). Lymphoid Pathology on Small Biopsies (FNA and Small Core)—Advantages and Limitations: Guidelines for Ancillary Studies According to Clinical Scenario and Morphology. *Practical Lymph Node and Bone Marrow Pathology: Frequently Asked Questions*, 53-85.
- Patel, M. M. Analysis of FNAC Findings in Children Aged 1-10 Years with Cervical Lymphadenopathy at a Tertiary Care Hospital. *Tuberculosis*, 11, 27-5.
- Toppo, S. M., & Punjaji, T. M. (2019). Spectrum of cytology findings in patients presenting with lymphadenopathy at tertiary health care centre in north Maharashtra region-A 2 year study. *Arch CytolHistopathol Res*, 4(2), 105-9.
- Singh, S., Omhare, A., Rajeev Ranjan, I., Rani, D., & Bharti, R. A cytological study of enlarged supraclavicular lymph nodes through fine needle aspiration.
- Parvin, S., Islam, M. S., Akter, K., Sadat, M. N., & Islam, R. (2023). Diagnostic efficacy of fine needle aspiration cytology in the evaluation of tuberculous lymphadenitis at the Diabetic Association Medical College, Faridpur, Bangladesh. *Journal of Medical and Dental Science Research*, 10(1), 47-55.
- Biswas, B., Chowdhury, A. S., Akter, S., Fatema, K., Reem, C. S. A., Tuhin, E., & Hasan, H. (2024). Knowledge and attitude about COVID-19 and importance

- of diet: A cross-sectional study among Bangladeshi people. *Bangladesh Journal of Food and Nutrition*, 1(1), 04-12.
15. Hussain, M. D., Rahman, M. H., & Ali, N. M. (2024). Investigation of Gauss-Seidel Method for Load Flow Analysis in Smart Grids. *Sch J Eng Tech*, 5, 169-178.
 16. Ali, M. E., Islam, M. S., Rahman, M. M., & Rahman, M. M. (2024). Functional Outcome of Closed Locked Intramedullary Nailing of The Femoral Shaft Fracture. *Asia Pacific Journal of Surgical Advances*, 1(1), 4-14.
 17. Raina, A., Rana, V. M., Qadir, R., & Atri, S. K. Cytological evaluation of cervical lymphadenopathy in a tertiary care centre, Govt. Medical College Kathua: Two year study.
 18. Ronchi, A., Caputo, A., Pagliuca, F., Montella, M., Marino, F. Z., Zeppa, P., ... & Cozzolino, I. (2021). Lymph node fine needle aspiration cytology (FNAC) in paediatric patients: Why not? Diagnostic accuracy of FNAC in a series of heterogeneous paediatric lymphadenopathies. *Pathology-Research and Practice*, 217, 153294.
 19. Sellami, M., Charfi, S., Chaabouni, M. A., Mrabet, S., Charfeddine, I., Ayadi, L., ... & Ghorbel, A. (2019). Fine needle non-aspiration cytology for the diagnosis of cervical lymph node tuberculosis: a single center experience. *Brazilian Journal of Otorhinolaryngology*, 85(5), 617-622.
 20. Tahseen, S. I., Naganna, S., & Gupta, G. (2022). Fine Needle Aspiration Cytology of Lymphnode Lesions in Correlation with Histopathology. *European Journal of Cardiovascular Medicine*, 12(4).
 21. Hashmi, A. A., Naz, S., Ahmed, O., Yaqeen, S. R., Irfan, M., Kamal, A., & Faridi, N. (2020). Utility of fine needle aspiration cytology in the evaluation of lymphadenopathy. *Cureus*, 12(12).
 22. Chaurasia, R. K., & Sharma, P. (2019). A cytological study of prevalence and pattern of tuberculosis at tertiary center Uttar Pradesh. *Int J Res Rev*, 6(12), 562-567.
 23. Kant, K., Baveja, C. P., Sarkar, J., & Juyal, D. (2019). Microbiological evaluation of clinically suspected cases of tubercular lymphadenopathy by cytology, culture, and smear microscopy—A hospital-based study from Northern India. *Journal of family medicine and primary care*, 8(3), 828-833.
 24. Hossain, Q., Yasmin, F., Biswas, T. R., & Asha, N. B. (2024). Data-Driven Business Strategies: A Comparative Analysis of Data Science Techniques in Decision-Making. *Sch J Econ Bus Manag*, 9, 257-263.
 25. Saleem, M. W., Hashmat, S., Rashid, A., Singh, D., Alam, S. A., & Fauzia, T. (2023). A Prospective Study Comparing Diagnosis of Neck Swellings by Fine Needle Aspiration Cytology with Histopathology. *Pakistan Journal of Medical & Health Sciences*, 17(06), 427-427.