

CASE REPORT



A Tale of a Rare Neuro-Rehabilitation: Dyke Davidoff Masoon Syndrome

Md. Ashikul Islam¹ *, Jas Bahadur Gurung², Shohag Chakrabarty³, Fatema Newaz⁴, Tapas Sarker⁵, Md. Taslim Uddin⁶

¹ Junior consultant, Dept. of PM & R, Manikganj Medical College Hospital, Manikganj

² Consultant Physical Medicine & Rehabilitation, Green Pastures Hospital & Rehabilitation Centre, Pokhara, Nepal

³ Junior Consultant, Dept. Of Physical Medicine and Rehabilitation, General Hospital, Cumilla

⁴ Assistant Professor, Dept. of PM & R, Kumudini Women's Medical College and Hospital

⁵ Resident Surgeon, Dept. of Neurosurgery, Kurmitola General Hospital, Dhaka

⁶ Professor & Ex-chairman, Dept. of PM & R, Bangabandhu Sheikh Mujib Medical University, Dhaka

ABSTRACT

Dyke-Davidoff-Masson Syndrome (DDMS) is a rare neurological disorder marked by cerebral hemiatrophy, presenting with contralateral hemiparesis, seizures, developmental delays, and facial asymmetry. This case report examines an 18-year-old male diagnosed with DDMS, who presented with right-sided weakness, impaired mobility, and speech difficulties that severely impacted his daily activities. Symptoms began at age eight, following an undocumented febrile episode, and progressively worsened, leading to significant functional limitations. MRI findings confirmed cerebral atrophy on the left side with compensatory hypertrophy of the right hemisphere, supporting a DDMS diagnosis. A multidisciplinary rehabilitation approach was implemented, led by a physiatrist and includes neurologist, psychiatrist, physiotherapist, occupational therapist, orthotist, speech therapist, vocational counselor etc. Over six months, the patient's Functional Independence Measure (FIM) score improved from 82 to 90 (9.8% increase), and his Barthel Index rose from 75 to 80 (6.7% increase). Gross motor, fine motor and speech clarity is also increased. This case highlights the importance of a structured, multidisciplinary approach in managing DDMS, demonstrating that significant functional gains and improved quality of life are achievable despite the challenges of this rare condition.

Keywords: Dyke-Davidoff-Masson Syndrome, Neuro-Rehabilitation, Cerebral Hemiatrophy, Functional Independence, Multidisciplinary Care.

| Submitted: 16.10.2024 | Accepted: 27.10.2024 | Published: 20.11.2024

*Corresponding Author

Dr. Md. Ashikul Islam, Junior consultant, Dept. of PM & R, Manikganj Medical College Hospital, Manikganj

Email: ashikpmrbd@gmail.com

How to Cite the Article

Md. Ashikul Islam, Jas Bahadur Gurung, Shohag Chakrabarty, Fatema Newaz, Tapas Sarker, Md. Taslim Uddin: A Tale of a Rare Neuro-Rehabilitation: Dyke Davidoff Masoon Syndrome. *IAR J Med Surg Res.* 2024;5(6): 66-72.

© 2024 IAR Journal of Medicine and Surgery Research, a publication of JMSRP Publisher, Kenya.

This is an open access article under the terms of the Creative Commons Attribution license.

(<http://creativecommons.org/licenses/by/4.0>).

(<https://jmsrp.or.ke/index.php/jmsrp>).

INTRODUCTION

Dyke-Davidoff-Masson Syndrome (DDMS) is a rare neurodevelopmental disorder that presents a

distinctive pattern of cerebral hemiatrophy, frequently accompanied by contralateral hemiparesis, intellectual disability, seizures, and facial asymmetry [1]. Originally

identified by Dyke, Davidoff, and Masson in 1933, this condition is associated with a suite of structural abnormalities, including atrophy of one cerebral hemisphere, thickening of the ipsilateral calvarium, and enlargement of the frontal sinuses and mastoid air cells—an adaptive response to cerebral volume loss [2]. Although DDMS can manifest in a congenital form, typically due to vascular malformations or in-utero ischemic events, it more commonly presents as an acquired condition in childhood, triggered by postnatal trauma, infections, or prolonged ischemic events that compromise blood flow to one hemisphere [3]. Clinically, DDMS is heterogeneous in its presentation, with symptoms varying according to the timing, extent, and severity of the cerebral insult. Most individuals exhibit unilateral motor weakness or hemiparesis on the side opposite the affected hemisphere, developmental delays, cognitive impairments, and behavioral issues, making functional independence challenging [4]. Moreover, the progressive nature of these neurological deficits and the underlying anatomical asymmetry create significant barriers to effective management. Patients often experience a deterioration in both cognitive and motor functions over time, complicating the rehabilitation process. For clinicians, this variability in presentation and prognosis demands a highly individualized approach to neuro-rehabilitation, where goals are centered on maximizing remaining functional abilities, enhancing quality of life, and preventing further disability [5].

Given the rarity of DDMS, there are no standardized protocols for treatment, and most rehabilitation strategies are based on case reports or small case series, highlighting the need for more empirical data [6]. The complex clinical profile of DDMS requires a multidisciplinary approach to care, integrating neurology, physical and occupational therapy, speech and language therapy, vocational and psychosocial support. Neurological consultations are essential to monitor and manage symptoms such as seizures and motor deficits. Physical therapy focuses on improving gait, balance, and coordination, while occupational therapy targets fine motor skills, aiming to restore some degree of independence in daily activities [7]. Speech therapy addresses communicative impairments, and psychosocial interventions play a crucial role in mitigating social isolation and enhancing psychological resilience in the face of chronic disability. In recent years, advancements in neuro-rehabilitation have opened new avenues for improving functional outcomes in rare neurological conditions like DDMS. Evidence suggests

that early intervention in motor and cognitive rehabilitation can foster neuroplasticity, helping the brain to reorganize and optimize its functional capabilities despite structural damage [8]. However, the lack of standardized care pathways, especially in resource-limited settings, presents a significant obstacle to achieving consistent outcomes. This report explores the case of A patient, a young male diagnosed with DDMS, and examines how a structured, interdisciplinary approach to neuro-rehabilitation can be adapted to meet the needs of patients with this rare condition, focusing on functional improvements, quality of life, and holistic, patient-centered care.

CASE PRESENTATION

A patient, an 18-year-old male, presented with chronic right-sided weakness in both the upper and lower limbs, impaired gait, and speech difficulties, which have significantly impacted his ability to perform daily activities. His symptoms began at the age of eight, following an undocumented episode of high fever, after which he experienced a gradual onset of weakness in his right limbs. Over the years, his physical and cognitive abilities progressively declined, affecting his academic performance and limiting his participation in outdoor and indoor activities. His speech has also become impaired, making communication challenging. A patient's birth history was uneventful, with no recorded complications, and he achieved normal developmental milestones up to the age of eight. There is no history of head trauma, seizures, or family history of neurological conditions. Prior to the onset of symptoms, he was active in academics and sports, with no reported behavioral or cognitive issues. However, as his condition progressed, he became increasingly dependent on family assistance for daily tasks, resulting in social withdrawal and decreased quality of life.

On physical examination, A patient exhibited pronounced motor impairment on the right side. His right upper limb showed a marked reduction in both gross and fine motor function, with significant weakness and limited range of motion. His right lower limb was also affected, with impaired balance and difficulty in walking, necessitating support for ambulation. Neurological examination revealed hyperreflexia on the right side and increased muscle tone, indicating spastic hemiparesis. Cognitive assessment revealed mild delays, particularly in tasks requiring complex instructions, likely due to long-term neurological impact. His speech was dysarthric, affecting clarity and fluency, further

limiting his social interactions. Functional assessments revealed a Functional Independence Measure (FIM) score of 82, reflecting moderate dependence on others for daily activities. His Barthel Index score was 75, indicating limitations in self-care and mobility. MRI of the brain confirmed left-sided cerebral hemiatrophy with compensatory hypertrophy of the right cerebral hemisphere, alongside thickening of the left-sided calvarium. These findings were consistent with a diagnosis of Dyke-Davidoff-Masson Syndrome (DDMS). In light of these findings, a multidisciplinary rehabilitation program was initiated, involving a team led by a physiatrist and including neurology, physical therapy, occupational therapy, speech therapy, and orthotic support. This integrated approach aimed to improve his functional independence, enhance motor skills, and support his communication abilities to improve his overall quality of life.

CLINICAL EXAMINATION

On clinical examination, A patient presented with marked right-sided hemiparesis. Muscle strength on the right side was significantly reduced, with upper limb strength graded at 2/5 and lower limb strength graded at 3/5 based on the Medical Research Council scale. The right upper limb exhibited a limited range of motion, particularly in flexion and extension, along with notable weakness in fine motor functions, such as grasping and pinching. Gross motor skills were impaired, impacting his ability to lift objects or perform coordinated movements. The right lower limb also demonstrated impaired balance and strength, resulting in an unsteady gait that necessitated support for ambulation. Neurological examination revealed increased tone and spasticity on the right side, indicative of upper motor neuron involvement. Hyperreflexia was evident, particularly in the right upper limb, along with a positive planter response, both of which suggested cortical involvement. Cranial nerve examination was within normal limits, with no evidence of deficits, indicating that cranial nerve function was preserved. Cognitive assessment revealed mild delays, with limitations in memory recall, processing speed, and understanding of complex instructions. These impairments may reflect long-standing neurological effects of cerebral hemiatrophy. His speech was dysarthric, with reduced clarity and disrupted rhythm, suggesting impaired motor control over speech-related musculature. Psychologically, A patient exhibited signs of social withdrawal, likely secondary to his physical impairments and communication difficulties. He expressed frustration

and low self-esteem, as he had become increasingly reliant on family members for assistance with daily tasks. These emotional and social challenges underscored the need for psychological support as part of his rehabilitation. The functional assessment included a Functional Independence Measure (FIM) score of 82, suggesting moderate dependence in daily tasks, and a Barthel Index score of 75, reflecting the extent of his limitations in self-care and mobility. Together, these assessments provided a comprehensive picture of A patient's physical, cognitive, and psychological impairments, guiding the formulation of his multidisciplinary rehabilitation program.

Investigations and Findings

An MRI of the brain revealed characteristic features of Dyke-Davidoff-Masson Syndrome (DDMS), confirming left-sided cerebral hemiatrophy. The left cerebral hemisphere showed significant cortical thinning and reduced gyri volume, resulting in a pronounced reduction in overall brain mass on the affected side. This atrophy was accompanied by ex vacuo dilatation of the lateral ventricle on the left side, a compensatory adaptation to the cerebral volume loss. Additional findings included thickening of the calvarium on the left side and enlargement of the frontal sinuses, both typical compensatory changes seen in DDMS. The right cerebral hemisphere displayed compensatory hypertrophy, likely reflecting adaptive growth in response to left-sided volume reduction. This hypertrophy contributed to maintaining overall cranial symmetry, despite the marked differences in cerebral volume between the hemispheres. No abnormalities were noted in the posterior fossa, brainstem, or cerebellum, and the sella and parasellar regions appeared normal. Other ventricular structures were symmetrically developed, ruling out any signs of obstructive hydrocephalus. Laboratory investigations, including a complete blood count, electrolyte panel, and liver and kidney function tests, were all within normal limits, effectively ruling out metabolic or systemic factors that could contribute to neurological deficits. An electroencephalogram (EEG) was not conducted due to the absence of clinical indications of seizure activity, as A patient had no history of seizures, a symptom often associated with DDMS but not present in this case. The diagnostic findings, particularly the MRI imaging, strongly supported a diagnosis of DDMS, given the classic presentation of unilateral cerebral atrophy, calvarial thickening, and compensatory changes on the contralateral side. The lack of head trauma or family history of neurological

conditions further suggested a congenital or early developmental onset. The results of these diagnostic tests, combined with clinical presentation, provided a definitive diagnosis and helped direct an appropriate rehabilitation strategy aimed at managing the syndrome's complex functional impairments.

DIAGNOSIS

Based on clinical presentation and MRI findings, A patient was diagnosed with Dyke-Davidoff-Masson Syndrome (DDMS). This rare neurological disorder, characterized by unilateral cerebral atrophy, often presents with contralateral motor weakness, developmental delays, and cognitive impairment. The

MRI findings of pronounced left-sided cerebral hemiatrophy, compensatory thickening of the calvarium, and right-sided hypertrophy are classic indicators of DDMS, further supported by A patient's history of progressive right-sided weakness and speech difficulties that began after an undocumented febrile illness at age eight. Given the absence of head trauma or seizure history, the syndrome likely has a congenital or early developmental onset. The diagnosis of DDMS informed the decision to implement a comprehensive, multidisciplinary rehabilitation program aimed at improving A patient's functional independence, mobility, and communication abilities, as well as addressing the psychological impact of his physical limitations.

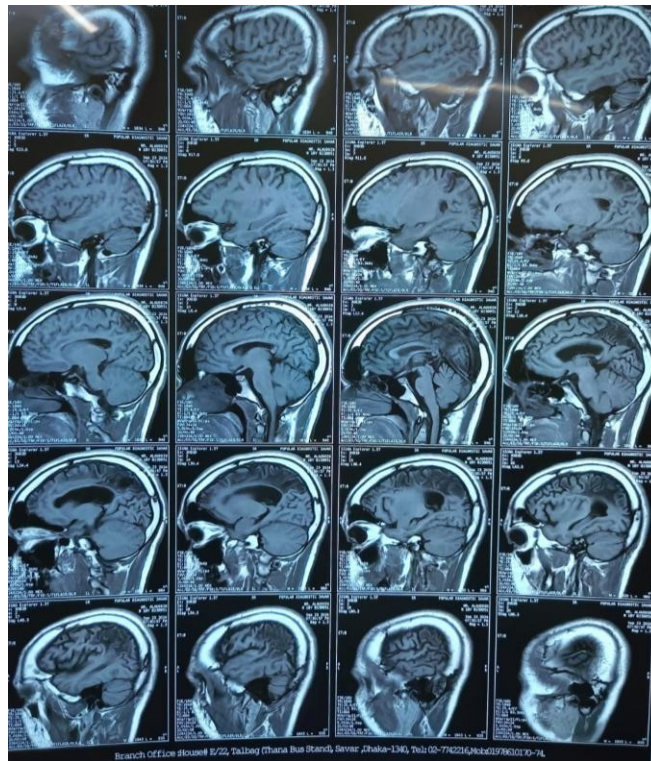


Figure 1: MRI Sagittal Views of the Brain Showing Left-Sided Cerebral Hemiatrophy Consistent with Dyke-Davidoff-Masson Syndrome

Multiple sagittal MRI images demonstrating significant left-sided cerebral hemiatrophy. The images show characteristic features associated with Dyke-Davidoff-Masson Syndrome, including prominent atrophy of the left cerebral hemisphere, compensatory hypertrophy of the right hemisphere, and thickening of the calvarium on the affected side.

Intervention and Management

A comprehensive, multidisciplinary rehabilitation program was implemented for A patient, targeting his motor, cognitive, and speech impairments under the coordination of a physiatrist. Neurology consultations provided ongoing monitoring to assess his neurological symptoms and address any new developments, even though he had no history of seizures. This oversight ensured a holistic understanding of his neurological health and facilitated coordination with

other specialists. Physical therapy focused on strengthening his right side through resistance training, weight-bearing activities, and stretching exercises to improve stability, manage spasticity, and enhance range of motion. These exercises significantly improved his walking stability, allowing him to gradually regain control over gross motor functions. Occupational therapy was vital in enhancing his independence in activities of daily living, focusing on grip strengthening and coordination exercises that improved his fine motor skills. Adaptive tools, such as modified utensils and dressing aids, were introduced to facilitate daily tasks, and energy conservation techniques allowed him to accomplish activities with greater efficiency, fostering a sense of autonomy. Speech therapy addressed his dysarthria, with exercises aimed at improving articulation, breath control, and rhythmic speech to enhance clarity and pronunciation. These sessions incorporated social communication strategies, empowering him to engage more effectively with family and peers. To further stabilize his gait and prevent foot drop, an ankle-foot orthosis (AFO) was fitted, which was closely monitored by an orthotist in collaboration with the physical therapist, contributing to a more balanced gait. Psychological counseling played a crucial role in supporting his emotional well-being, helping him cope with the social isolation resulting from his physical limitations. Through group activities and individual sessions, he built self-confidence, established social connections, and stayed motivated to commit to the program. This integrated approach allowed each specialist to address his unique needs, enhancing his functional independence and quality of life. The collaborative effort ensured that interventions were responsive to his progress, adapting as new challenges emerged, thereby offering a comprehensive pathway toward improved well-being and independence.

Outcomes and Follow-Up

His Functional Independence Measure (FIM) score increased from 82 to 90, reflecting a 9.8% enhancement in his ability to perform daily activities independently. His Barthel Index score rose from 75 to 80 (6.7% increase), representing an increase in his self-care abilities with minimal assistance. Motor function is also improved both in gross motor and fine motor control. In terms of communication, his speech clarity improved, enabling more effective and confident interaction, which reduced social withdrawal and improved his engagement with family and peers.

DISCUSSION

Dyke-Davidoff-Masson Syndrome (DDMS) is a rare neurological disorder that presents complex rehabilitation challenges due to its characteristic cerebral hemiatrophy and associated motor, cognitive, and speech impairments. In DDMS, cerebral atrophy typically occurs on one hemisphere, often leading to contralateral hemiparesis, seizures, and developmental delays [9]. This case underscores the importance of a structured, multidisciplinary approach in managing DDMS, where targeted interventions can improve functional independence and enhance quality of life. Study on DDMS has emphasized the importance of early intervention to leverage neuroplasticity, allowing for functional reorganization within the brain's existing neural structures [10]. Although DDMS lacks a standardized treatment protocol due to its rarity, combining physical therapy, occupational therapy, and speech therapy has shown to be beneficial in case studies for improving motor function, daily living skills, and communication [11]. In A patient's case, physical therapy was integral to improving gross motor skills and gait stability, while occupational therapy facilitated his ability to perform daily tasks, promoting greater autonomy and independence [12].

One of the primary challenges in DDMS rehabilitation is addressing the syndrome's multifaceted impact on motor, cognitive, and social domains, which often requires sustained, adaptive support from a multidisciplinary team. Studies have highlighted that custom orthotic device, such as ankle-foot orthoses, are instrumental in stabilizing gait and reducing the risk of falls, as seen in A patient's treatment plan [13]. Additionally, speech therapy's focus on articulation and breath control has been shown to aid in improving communication and reducing social isolation, further enhancing the patient's quality of life [14,15]. In settings with limited resources, prioritizing interventions for mobility and daily living tasks can yield significant improvements in quality of life for DDMS patients. Psychological support is also critical, as emotional distress and social withdrawal are common in patients with prolonged dependence on caregivers [16]. In A patient's case, counseling sessions were essential in addressing these psychosocial challenges, enhancing his confidence and supporting his social reintegration. This case highlights the need for further research on DDMS rehabilitation, as most available evidence comes from isolated case studies. Establishing more comprehensive, standardized protocols for DDMS care would provide

clinicians with better guidance in optimizing neuro-rehabilitation strategies and maximizing functional outcomes for patients with this rare condition [17].

CONCLUSION

This case highlights the effectiveness of a multidisciplinary rehabilitation approach in managing Dyke-Davidoff-Masson Syndrome (DDMS), a rare neurodevelopmental disorder. Through structured interventions in physical therapy, occupational therapy, and speech therapy, A patient demonstrated significant improvements in independence, motor skills, and communication. This case underscores the potential of personalized, holistic care to improve quality of life in DDMS patients and emphasizes the need for further research to develop standardized rehabilitation protocols for rare neurological conditions.

Funding: No funding sources

Conflict of interest: None declared

REFERENCES

- Thakkar, P. A., & Dave, R. H. (2016). Dyke–Davidoff–Masson syndrome: A rare cause of cerebral hemiatrophy in children. *Journal of pediatric neurosciences*, 11(3), 252-254.
- Tan, A. P., Wong, Y. L. J., Lin, B. J., Yong, H. R. C., & Mankad, K. (2018). Clinico-radiological approach to cerebral hemiatrophy. *Child's Nervous System*, 34, 2377-2390.
- Abdul Rashid, A. M., & Md Noh, M. S. F. (2018). Dyke-Davidoff-Masson syndrome: a case report. *BMC neurology*, 18, 1-3.
- Tsirir, G., Spiro, N., & Pavlicevic, M. (2018). Repositioning music therapy service evaluation: A case of five Nordoff-Robbins music therapy service evaluations in neuro-rehabilitation. *Nordic Journal of Music Therapy*, 27(1), 3-27.
- Kalaskar, R., & Kalaskar, A. R. (2018). Classical oral manifestations of Dyke-Davidoff-Masson syndrome: a case report with review of the literature. *Journal of the Korean Association of Oral and Maxillofacial Surgeons*, 44(4), 198-203.
- Diestro, J. D. B., Dorotan, M. K. C., Camacho, A. C., Perez-Gosiengfiao, K. T., & Cabral-Lim, L. I. (2018). Clinical spectrum of Dyke-Davidoff-Masson syndrome in the adult: an atypical presentation and review of literature. *Case Reports*, 2018, bcr-2018.
- Mills, S. J., McDonnell, M. N., Thewlis, D., & Mackintosh, S. (2017). Is there a relationship between postural alignment and mobility for adults after acquired brain injury? A systematic review. *Brain injury*, 31(5), 571-580.
- Matamala Gómez, M. (2017). The use of immersive virtual reality in neurorehabilitation and its impact in neuroplasticity.
- Duncan, M. A., Vázquez Flores, S., Chávez Lluévamos, E. B., Cantú Salinas, A. C., De León Flores, L., & Villarreal Velázquez, H. J. (2014). Dyke-Davidoff-Masson syndrome: A case study. *Medicina universitaria*, 16(63), 71-73.
- Frias, E. S. (2021). *Dissecting the Mechanisms of Brain Injury for Treatment of Cognitive Dysfunctions*. University of California, San Francisco.
- Harris, M., Thomas, G., Thomas, M., Cafarella, P., Stocks, A., Greig, J., & McEvoy, R. D. (2018). Supporting wellbeing in motor neurone disease for patients, carers, social networks, and health professionals: A scoping review and synthesis. *Palliative & supportive care*, 16(2), 228-237.
- Singh, A. S., Saliasi, E., Van Den Berg, V., Uijtdewilligen, L., De Groot, R. H., Jolles, J., ... & Chinapaw, M. J. (2019). Effects of physical activity interventions on cognitive and academic performance in children and adolescents: a novel combination of a systematic review and recommendations from an expert panel. *British journal of sports medicine*, 53(10), 640-647.
- Padilla, M. G., Rueda, F. M., & Diego, I. A. (2014). Effect of ankle-foot orthosis on postural control after stroke: a systematic review. *Neurología (English Edition)*, 29(7), 423-432.
- Saini, D. S., Satpathi, A., Pandit, A., & Ganguly, G. (2017). Case Report of an interesting case of hemiparesis with resistant epilepsy-Dyke, Davidoff, and Masson syndrome. *Indian Journal of Neurosciences*, 3(1), 44-46.
- Ayas, Z. Ö., Asil, K., & Öcal, R. (2017). The clinico-radiological spectrum of Dyke-Davidoff-Masson syndrome in adults. *Neurological Sciences*, 38, 1823-1828.
- Mosher, C. E., Ott, M. A., Hanna, N., Jalal, S. I., & Champion, V. L. (2015). Coping with physical and psychological symptoms: a qualitative study of advanced lung cancer patients and their family caregivers. *Supportive Care in Cancer*, 23, 2053-2060.

17. Ayele, B. A., & Zewde, Y. Z. (2019). Dyke–Davidoff–Masson syndrome-a rare cause of cerebral Hemiatrophy in a 17-years-old Ethiopian patient: a case report. *Ethiopian journal of health sciences*, 29(2).