



Benign tumors of Eyelid: A 10 years' experience from Nepal

Article History
Received: 20.04.2021 Revision: 30.04.2021 Accepted: 10.05.2021 Published: 20.05.2021 Plagiarism check - Plagscan
Author Details
Ben Limbu ^{1*} , Suresh Rasaily ² and Rohit Saiju ¹
Authors Affiliations
¹ Department of Oculoplasty, Tilganga Institute of Ophthalmology, Kathmandu, Nepal
² Rapti Eye Hospital, Dang, Nepal
Corresponding Author*
Ben Limbu
How to Cite the Article:
Ben Limbu, Suresh Rasaily & Rohit Saiju. (2021). Benign tumors of Eyelid: A 10 years' experience from Nepal. <i>IAR J Med & Surg Res</i> , 2(3), 14-19
Copyright @ 2021: This is an open-access article distributed under the terms of the Creative Commons Attribution license which permits unrestricted use, distribution, and reproduction in any medium for non commercial use (NonCommercial, or CC-BY-NC) provided the original author and source are credited.

Abstract: *Aim:* The aim was to describe the epidemiology of primary benign eyelid tumors over a 10-year period at one of the tertiary eye care centers in Nepal. *Method:* This is a retrospective, a hospital-based study in which we reviewed the medical records of all patients with histologically confirmed benign eyelid tumors who were operated on at our institute over a period of 10 years from January 2006 to December 2016. Data were collected based on age, gender, location of the lesion, clinical and histological diagnosis, types of surgery, and recurrence. A total of 477 patients with histopathology reports were included in the study and benign eyelid tumors were categorized as epidermal, Adnexal, and Stromal. Data analysis was done using SPSS 16.0. The study was conducted after ethical approval from Institutional Review Committee, and adhered to the tenets of the Declaration of Helsinki. *Results:* Out of a total of 477, 214 (44.9%) patients were male and 263 (55.1%) were female. The mean age of presentation was 35.36± 19.6 (range 1-93) years. The most common complaint was eyelid mass (91.2%) and the mean duration of presentation and follow-up was 43.46 ±78.55 and 15.88± 13.87 months respectively. The lower lid 206 (43.2%) was the most common site for tumor and local excision with direct closure was commonly performed procedure 291(61%). Overall, the most common histopathological diagnosis was Nevus 108 (22.6%) followed by Squamous Papilloma 58 (12.1%), epidermal cyst 52 (10.9%), capillary hemangioma 37(7.7%), and sebaceous cyst 36 (7.5%). We found clinical diagnosis matched with a histopathological report in 326 (68.3%) patients. However, 18 patients (3.77%) clinically judged as malignant were confirmed to be benign on the histopathological report. Recurrence of eyelid tumor was seen among 7 (1.5%) and out of which capillary hemangioma reoccurred in 2 (28.6%). *Conclusions:* The majority of our patients presented with eyelid mass frequently located in the lower lid and diagnosed as nevi on the histopathological report. However, clinical misdiagnosis was found in 31.7% of cases where clinically suspected malignant tumors 3.77% turned to be benign on histopathology. We recommend routine histopathological evaluation of all the surgically excised eyelid tumors and also aware patients of the possibility of recurrence of benign eyelid tumors.

Keywords: Benign; Eyelid; Histopathology; Tumors; Nevus.

INTRODUCTION

Benign eyelid tumors are the most common presentation of eyelid lesions in all age group patients accounting for 5% of skin tumors occurrence in eyelids (Cook, Jr. *et al*, 2001). Eyelid tumors not only give unnecessary psychological fear or malignancy but also poses significant esthetic challenges (Hilosky JP,1995). The benign lesions most commonly encountered by the ophthalmologist are chalazia, epidermal inclusion cysts, seborrheic keratosis, and apocrine hydrocystomas. The premalignant conditions include actinic keratosis, Bowen's disease, and keratoacanthoma (Bernardini FP, 2006). Nepal has different geographical terrain with different altitude levels (<https://en.wikipedia.org/wiki/Nepal#Geography>). Geographic and climate conditions can also influence the frequency of the different types of benign eyelid masses as reported by various literature. The most common eyelid tumor was reported to be Nevi in (Bagheri, A. *et al.*, 2013) study, papilloma in (Kersten, RC. *et al.*, 1997) study from the USA and (Ni Z, 1996) from Shanghai, dermoid cysts in (Lin, H. Y *et al.*, 2004) from Taiwan, and hydrocystomas in (Al-Faky Y. H, 2012) from Saudi. However, there is limited literature on the profile of benign eyelid tumors in the Nepalese population. So, we conducted this study to identify the pattern of benign eyelid tumors in the Nepalese population over a period of 10 years.

METHODOLOGY

A retrospective hospital-based study was conducted after obtaining ethical approval from an institutional review committee and the study adhered to the tenets of the Declaration of Helsinki. The patients with benign eyelid tumors who had undergone excisional biopsy at our hospital over a period of 10 years were reviewed. Only patients with histopathology report of benign eyelid tumors after exclusion of chalazion were included whereas patients with histopathological proven malignant tumors, patients without histopathology report, incomplete information, and lost to follow up within a month of surgery were excluded from the study. Out of 592, only 477 patients were found to be eligible for this study.

Data were collected on patient age, gender, location of the lesion, clinical and histological diagnosis, types of surgery, and recurrence. Based on the histopathology findings of tumors, they were categorized as epidermal, Adnexal, Stromal, and Others. The data were entered in Microsoft Excel 2016 (Microsoft Corporation, Redmond, Washington, USA) and statistically analyzed using Statistical Package for Social Sciences version 16 (SPSS, Inc.)

RESULT

A total of 487 benign eyelid tumor surgeries in 477 patients were analyzed and the mean age of patients was 35.36± 19.6 (range 1 to 93) years. Out of total patients, 214 (44.9%) were male and 263

(55.1%) were female with a male: female ratio of 1:1.2. The majority of patients 359 (75.3%) were from the Hilly region followed by plain 86(18%) and mountain 31(6.5%). Majority of patients presented with eyelid mass 91.2%, heaviness of eyelid 7.3%, bleeding from eye 1.3%, and wound in eyelid 0.2%. The mean duration of chief complaint was 43.46 ±78.55 (range 1 – 580) months and the mean duration of follow-up was 15.88± 13.87 months. Detailed demographic characteristics of the study population are as shown in Table 1. The most common site for the tumor was the lower eyelid 206(43.2%) followed by upper eyelid 180 (37.7%), Medial canthus 62 (13%), and lateral canthus 29 (6.1%).

Table 1. Demographic characteristics among the study populations

Characteristics	No. of Patients n = 477	Percentage
Mean Age	35.36 ±19.6 (1 - 93) years	
Male /Female	214/263	44.9/55.1
Geographical distribution		
Plain or Terai	86	18
Hill	360	75.5
Mountain	31	6.5
Presenting complaint		
Mass in eyelid	435	91.2
Heaviness eyelid	35	7.3
Bleeding from eyelid	6	1.3
Wound eyelid	1	0.2
Mean duration of presenting complaint	43.46 ±78.55(1 - 580)months	
Mean duration of follow up	15.88 ±13.87 (1 - 103) months	

In our study, clinical diagnosis was matched to histopathological diagnosis in 326 patients (68.3%), whereas 18 (3.77%) patients judged to be malignant eyelid tumors were found to be benign on the histopathological report. The most common surgical procedure performed for eyelid tumors was excisional biopsy with direct closure in 291 (61%) cases followed by excision shave excisional biopsy 90(18.8 %). The different surgical procedures with reconstruction are as shown in Figure 1. Overall, the most common histopathological diagnosis was

Nevus 108 (22.6%) followed by Squamous Papilloma 58 (12.1%), epidermal cyst 52 (10.9%), capillary hemangioma 37 (7.7%), sebaceous cyst 36 (7.5%), granuloma 36 (7.5%), cyst of moll 21 (4.4%) and lipodermoid 18 (3.7%) respectively. Clinical diagnosis was matched to histopathological diagnosis in 326 (68.3%) patients however 18 patients (3.77%) clinically judged as malignant eyelid tumors were found to be benign eyelid tumors on the histopathological report as shown in Table 2.

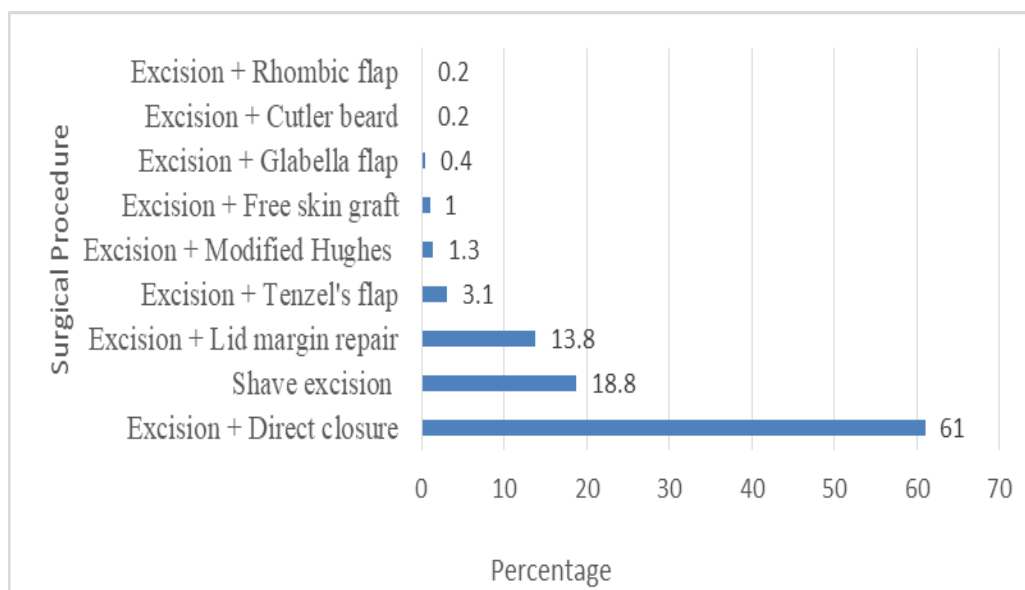


Figure 1: Distribution of surgical procedure.

Table 2. Clinically misdiagnosed as malignant but histologically benign tumor distributions

Clinical Diagnosis	No. of Pt (n=18)	Histopathological Diagnosis
Basal Cell Carcinoma	3	Granuloma
	3	Intradermal Nevus
	2	Seborrheic Keratosis
	1	Squamous Papilloma
	1	Epidermal Cyst
	1	Syringo cystoadenoma
	1	Amyloidosis
	1	Pleomorphic Adenoma
	Melanoma	1
1		Epidermal Cyst
1		Intradermal Nevus
Lymphoma	1	Xanthelasma
Sebaceous Cell Carcinoma	1	Pilomatrixoma

Table 3. Distribution of epidermal tumors of eyelid

Type of Tumor	Number n=232	Mean Age in years (SD)	Sex Ratio M:F	Mean Duration of Symptoms in Months (SD)	Lateral ity [¥]	Upper Lower [£]	Reurrence(%)	Mean FU(SD)
Melanocytic tumors								
Nevus	108	35.71(17.86)	1:2.48	79.38(112.94)	R 53 L 55	U 42 L 49 M 15 LC 2	0.00	16.02(13.02)
Lentigo Simplex	1	39	0:1	24	L 1	L 1	0.00	15
Non melanotic tumors								
Squamous Papilloma	58	37.26(20.08)	1:1.52	35.97(62.57)	R 30 L 26 B 2	U 25 L 27 M 3 LC 2	1(1.7)	15.14(12.71)
Epidermal Cyst	52	39.38(19.12)	1:0.67	34.54(44.92)	R 26 L 26	U 21 L 17 M 10 L 4	1(0.9)	16.21(12.74)
Seborrheic Keratosis	11	49.45(18.07)	1:4.5	20.82(28.21)	R 4 L 7	U 4 L 7	0.00	17.09(12.41)
Keratoacanthoma	2	65(21.21)	1:1	7.50(9.19)	R 2	U 1 L 1	0.00	13(5.65)

Note - [¥]R = Right eye, L = Left eye; [£]U = upper lid, L = Lower lid, M = medial canthus, LC lateral canthus

Table 4. Adnexal eyelid tumors distribution among study population

Type of Tumor	Number n=93	Mean Age in years (SD)	Sex Ratio M:F	Mean Duration of Symptoms in Months (SD)	Lateral ity	Upper Lower	Recurrence	Mean FU(SD)
Sebaceous gland tumor								
Sebaceous cyst	36	35.44(22.18)	1:0.8	16.81(26.63)	R 19 L 16 B 1	U 14 L 15 M 6 L 1	0.00	13.83(9.77)
Cyst of Moll	21	46.76(24.93)	1:0.9	18.24(17.87)	R 11 L 10	U 7 L 10 M 4	0.00	13.81(10.09)
Cyst of Zeis	4	33.75(7.89)	1:1	71.75(119.20)	R 1 L 3	U 1 L 3	0.00	9(4.4.08)
Sebaceous hyperplasia	1	55	0:1	12	L 1	L 1	0.00	60
Tumor of eccrine and apocrine origin								
Sudoriferous Cyst	13	49.46(15.36)	1:0.85	44.31(93.63)	R 9 L 4	U 3 L 6 M 2 L 2	0.00	14.15(11.67)
Apocrine Hydrocystoma	2	55.50(7.77)	0:2	18(8.48)	L 2	L 2	0.00	10.5(4.95)
Syringoma	1	4	1:0	12	L 1	U 1	0.00	13
Sringocystadenoma	1	57	1:0	120	L 1	L 1	0.00	13
Hair Follicle tumor								
Pilomatrixoma	10	30(18.33)	0:10	12.70(17.90)	R 3 L 7	U 9 L 1	0.00	10.50(3.77)
Trichelemmal Cyst	3	42.33(7.37)	1:2	16.33(17.09)	R 2 L 1	U 2 L 1	0.00	8.67(4.61)
Trichofolliculoma	1	11	1:0	12	R 1	U 1	0.00	60

Note - [¥] R = Right eye, L = Left eye; [£] U = Upper lid, L = Lower lid, M = medial canthus, LC lateral canthus

Table 5. Stromal eyelid tumors distributions among study group

Type of Tumor	Number n=133	Mean Age in years (SD)	Sex M:F	Mean Duration of Symptoms in Months (SD)	Lateral ity	Upper Lower	Recurrence (%)	Mean FU(SD)
Vascular tumor origin								
Capillary Hemangioma	37	26.49(19.28)	1:0.76	11.19(33.36)	R 19 L 18	U 16 L 17 M 3 LC 1	1(2.7)	17.41(16.19)
Granuloma	36	25.83(17.99)	1:1.11	8.56(15.16)	R 16 L 20	U 10 L 19 M 5 LC 2	0.00	13.47(13.38)
Cavernous Hemangioma	7	22.29(9.44)	1:0.4	72.71(47.28)	R 4 L 3	U 3 L 4	0.00	23.86(18.56)
Xanthomatous tumor of eyelids								
Xanthelasma	9	40.33(11.96)	1:1.25	21.22(18.99)	R 2 L 1 B 6	U 7 L 1 M 1	0.00	14.22(8.75)
Neural Tumors								
Schwannoma	3	20(6.92)	1:0.5	22.33(22.36)	L 3	U 1 L 2	1(33.3)	14.67(3.05)
Fibrous tissue tumor								
Fibroepithelial Polyp	3	29.33(6.65)	1:0.5	17(26.28)	R 1 L 2	L 3	0.00	36.67(46.28)
Benign Fibrous Histiocytoma	3	34.33(14.36)	1:0.5	8.67(5.77)	L 3	U 2 L 1	0.00	9.67(2.08)
Lymphoid tumor								
Reactive Lymphoid Hyperplasia	2	38.50(21.92)	1:1	7.50(2.12)	L 2	M 2	0.00	14(2.82)
Lymphangioma	1	59	1:0	12	R 1	L 1	0.00	12
Hemartoma and Choriostoma								
Lipodermoid	18	27.22(17.44)	1:0.8	123.78(112.68)	R 11 L 6 B 1	M 3 L 15	0.00	15.17(8.65)
Dermoid Cyst	14	40.71(17.92)	1:0.75	69.43(120.66)	R 10 L 4	U 3 L 4 LC 7	1(7.1)	22.43(20.30)

Note - [¥] R = Right eye, L = Left eye; [£] U = Upper lid, L = Lower lid, M = medial canthus, LC lateral canthus

Table 6. Others types of eyelid tumors among study population

Type of Tumor	Number n = 19	Mean Age in years (SD)	Sex M:F	Mean Duration of Symptoms in Months (SD)	Later ality	Upper Lower	Recurren ce (%)	Mean FU(SD)
Molluscum Contagiosum	11	26.64(14.49)	1:1.7	29.91(70.35)	R 5 L 6	U 4 L 7	0.00	10.73(4.94)
Calcinosis Cutis	2	17(4.24)	1:1	120.50(168.99)	R 1 L 1	U 1 L 1	0.00	31.50(23.33)
Verruca Vulgaris	1							
Amyloidosis Canalicualr	1	25	0:1	120	L 1	L 1	0.00	28
Lithiasis Chronic	1	42	1:0	12	R 1	L 1	0.00	7
Dacroadenitis	1	3	1:0	36	L 1	U 1	0.00	14
Pleomorphic adenoma	1	66	1:0	228	L 1	L 1	0.00	103
Folliculitis	1	26	0:1	6	R 1	M 1	0.00	12

Note - [¥] R = Right eye, L = Left eye; [£] U = Upper lid, L = Lower lid, M = medial canthus, LC lateral canthus

We categorized benign eyelid tumors based on the histopathological reports as shown in Tables 3, 4, 5, and 6. We also encountered rare tumor-like Schwannoma, syringoma, and amyloidosis on histopathological examination reports as illustrated in Tables. In our study recurrence of the tumor was noted in 7 (1.5%) patients out of which revision surgery was done in 5 patients and intraregional triamcinolone was given in 2 patients.

DISCUSSION

The prevalence of benign eyelid tumors has been found to differ in various geographical terrain and climate of the country. Nepal lies between latitudes 260 and 310 N and longitudes 800 and 890. It has tropical and subtropical zones lying below 1200 meters to Arctic zones above 4400 meters (<https://en.wikipedia.org/wiki/Nepal#Geography>). The mean age of patients in our study was 35.36 ± 19.6 years which is similar to the other studies (Laila HM *et al.*, 2012 and Rathod A, *et al.* 2015). However, higher Mean age of patients 46.4 ± 20.7 years was reported in other studies (Chi MJ. 2006 and Bagheri, A. *et al.*, 2013).

In our study, the most common histopathological diagnosis was Nevus 108 (22.6%) followed by Squamous Papilloma 58 (12.1%), epidermal cyst 52 (10.9%), capillary hemangioma 37(7.7%). Similarly, other studies (Pant, N. *et al.*, 2020 and Bastola, P. *et al.*, 2013) done in Nepal found nevi (26.5%) and dermoid cyst (21%) as the most common benign eyelid tumors respectively. However, a study from Taiwan (Huang, YY. *et al.*, 2015) 15 reported intradermal nevi (21.1%) as the most common benign eyelid tumors followed by seborrheic keratosis (12.6%) and xanthelasma. (11.2%).

The most common site for eyelid tumor involvement in our study was lower eyelid 43.2%, upper lid

37.7%, medial canthus 13%, and lateral canthus 6.1% respectively. A similar finding was seen by (Ho, M. *et al.*, 2013, Bagheri, A. *et al.*, 2013, Rathod, A. *et al.*, 2015, Karan, S. *et al.*, 2016 and Paul, R. *et al.*, 2017). We also observed 3.77% of our patients clinically judged to be a malignant eyelid tumor turned to be benign eyelid tumor. Similar to our findings diagnosis inaccuracy was noted to be 11.6% and 1.9 % (Kersten, RC. *et al.*, 1997 and Margo, CE. 1999). The existence of clinical and histological diagnosis inaccuracy may be due to the surgeon's clinical experience and inconsistent form of disease presentation in various morphological forms.

We found recurrence of eyelid tumor in 7 (1.5%) patients in which surgery was repeated in 5 recurrent cases and 2 were managed by intraregional triamcinolone injection. Among the recurrent cases, 2 were capillary hemangioma and one each of granuloma, schwannoma, dermoid cyst, squamous papilloma, and epidermal cyst. The tumor recurrence with benign lid tumors rate was higher (4.4%) in a study from Taiwan (Huang, YY. *et al.*, 2015) as compared to our study.

CONCLUSION

The leading benign eyelid tumor was found to be Nevi, followed by Squamous papilloma, and an epidermal cyst on histological examination. The clinician should suspect these common pathologies as most occurring benign eyelid tumor, moreover, a significant proportion of disagreement among clinically suspected lesions for malignancy turned to be a benign tumor (3.77%) on histological examination. These findings mandate the indication of routine histopathological examination of all eyelid tumors removed surgically.

REFERENCES

1. Cook Jr, B. E., & Bartley, G. B. (2001). Treatment options and future prospects for the management of eyelid malignancies: an evidence-based update. *Ophthalmology*, *108*(11), 2088-2098.
2. Hilovsky, J. P. (1995). Lid lesions suspected of malignancy. *Journal of the American Optometric Association*, *66*(8), 510-515.
3. Bernardini, F. P. (2006). Management of malignant and benign eyelid lesions. *Current opinion in ophthalmology*, *17*(5), 480-484
4. <https://en.wikipedia.org/wiki/Nepal#Geography>.
5. Bagheri, A., Tavakoli, M., Kanaani, A., Zavareh, R. B., Esfandiari, H., Aletaha, M., & Salour, H. (2013). Eyelid masses: a 10-year survey from a tertiary eye hospital in Tehran. *Middle East African journal of ophthalmology*, *20*(3), 187.
6. Kersten, R. C., Ewing-Chow, D., Kulwin, D. R., & Gallon, M. (1997). Accuracy of clinical diagnosis of cutaneous eyelid lesions. *Ophthalmology*, *104*(3), 479-484.
7. Ni Z. Histopathological classification of 3,510 cases with eyelid tumor. [Zhonghua yan ke za zhi] Chinese journal of ophthalmology. 1996 Nov 1;32(6):435-7.
8. Lin, H. Y., Cheng, C. Y., Hsu, W. M., Kao, W. L., & Chou, P. (2006). Incidence of eyelid cancers in Taiwan: a 21-year review. *Ophthalmology*, *113*(11), 2101-2107.
9. Al-Faky, Y. H. (2012). Epidemiology of benign eyelid lesions in patients presenting to a teaching hospital. *Saudi Journal of Ophthalmology*, *26*(2), 211-216.
10. ELSHAZLY, L. H. (2012). Eyelid tumours: A clinicopathological study. *Med. J. Cairo Univ*, *80*(2), 95-101.
11. Rathod, A., Pandharpurkar, M., Toopalli, K., & Bele, S. (2015). A clinicopathological study of eyelid tumours and its management at a tertiary eye care centre of Southern India. *MRIMS Journal of Health Sciences*, *3*(1), 54.
12. Baek, S. H., & Chi, M. J. (2006). Clinical analysis of benign eyelid and conjunctival tumors. *Ophthalmologica*, *220*(1), 43-51.
13. Pant, N., Shrestha, G., Joshi, S., & Bhatta, S. (2020). Profile of Ophthalmic Tumors in Adult Nepalese Population in Central Nepal. *Nepalese Journal of Ophthalmology*, *12*(2), 270-280
14. Bastola, P., Koirala, S., Pokhrel, G., Ghimire, P., & Adhikari, R. K. (2013). A clinico-histopathological study of orbital and ocular lesions; a multicenter study. *Journal of Chitwan Medical College*, *3*(2), 40-44.
15. Huang, Y. Y., Liang, W. Y., Tsai, C. C., Kao, S. C., Yu, W. K., Kau, H. C., & Liu, C. J. (2015). Comparison of the Clinical Characteristics and Outcome of Benign and Malignant Eyelid Tumors: An Analysis of 4521 Eyelid Tumors in a Tertiary Medical Center. *BioMed research international*, *2015*, 453091. <https://doi.org/10.1155/2015/453091>
16. Liu, D. T., Ho, M., Chong, K. K., Lam, D. S., & Ng, H. K. (2013). Eyelid tumours and pseudotumours in Hong Kong Reply. *HONG KONG MEDICAL JOURNAL*, *19*(3), 277-277.
17. Karan, S., Nathani, M., Khan, T., Ireni, S., & Khader, A. (2016). Clinicopathological study of eye lid tumors in Hyderabad-A review of 57 cases. *Journal of Medical & Allied Sciences*, *6*(2).
18. Paul, R., Islam, M. N., Kabir, E., Khan, H. R., & Kundu, U. K. (2017). Tumors of the eyelid-a histopathological study at tertiary care hospitals in Dhaka, Bangladesh. *IMC Journal of Medical Science*, *11*(1), 5-10.
19. Margo, C. E. (1999). Eyelid tumors: accuracy of clinical diagnosis. *American journal of ophthalmology*, *128*(5), 635-636.