



Unusual Cause for Post Pregnancy Abdominal Bulge: A Large Desmoid Tumor

Article History
<p>Received: 10.04.2021 Revision: 20.04.2021 Accepted: 30.04.2021 Published: 10.05.2021 Plagiarism check - Plagscan</p>
Author Details
<p>Kusum Meena¹, Manchikanti Dinesh² and M M Ramshankar³</p>
Authors Affiliations
<p>¹Professor Department of General Surgery, Lady Hardinge Medical College, New Delhi, India ²Post graduate, Department of General Surgery, Lady Hardinge Medical College, New Delhi, India ³Associate Professor, Department of General Surgery, Army College of Medical Sciences, New Delhi, India</p>
Corresponding Author*
<p>Kusum Meena</p>
How to Cite the Article:
<p>Kusum Meena, Manchikanti Dinesh, & M M Ramshankar. (2021). Unusual Cause for Post Pregnancy Abdominal Bulge: A Large Desmoid Tumor. <i>IAJ Med & Surg Res</i>, 2(3), 10-13</p>
<p>Copyright @ 2021: This is an open-access article distributed under the terms of the Creative Commons Attribution license which permits unrestricted use, distribution, and reproduction in any medium for non commercial use (NonCommercial, or CC-BY-NC) provided the original author and source are credited.</p>

Abstract: Desmoid tumors are rare tumors which have shown a recent change in treatment from surgical option to more conservative modalities including use of novel molecular targeted therapy in form of receptor kinase inhibitors. More understanding towards tumor biology and behaviour brought the concept of individualized treatment for this rare tumor. Abdominal wall desmoid tumors have predilection for female patients of reproductive age group and watchful waiting can be judiciously used as therapeutic option in a large number of cases after more familiarity with tumor biology.

Keywords: Desmoid tumors, individualized treatment.

INTRODUCTION

Desmoid tumours are rare tumours with reported incidence of 2-4 per million population and constitute 0.03% of all neoplasms. These tumours can involve extremities, abdominal wall and abdominal mesentery and show preponderance for female gender and seen in reproductive age group ladies. Mutation that activates beta catenin has been linked as cause and instead of non-metastasizing property these tumours are difficult to manage owing to variability in tumor presentation and overall behaviour. An armamentarium of treatment includes surgery, chemotherapy, radiotherapy, hormone therapy and isolated limb perfusion therapy for aggressive fibromatosis of extremities and molecular targeted therapy (Shield, C.J. *et al.*, 2001).

The term desmoid was coined by Muller in 1838 and it has derived its name from Greek word desmos meaning tendon like. Aggressive fibromatosis, deep fibromatosis, musculoaponeurotic fibromatosis, non-metastasizing fibrosarcomas, fibro-myxoid sarcomas are commonly used to describe desmoid tumors. (Kumar, V. *et al.*, 2009) Desmoid tumor is called aggressive as it has similarities with a malignant tumor fibrosarcoma however it is considered benign as it does not metastasize. For abdominal wall desmoids infra umbilical region is common and precede with previous history of surgery in many. Symptoms of desmoid tumors depends on size and location and can be

- 1) A painless swelling or lump
- 2) Pain or soreness caused by compressed nerves or muscle
- 3) Pain or obstruction of bowel
- 4) Limping or other difficulty using the legs, feet, arms, hands or other affected part of body

CASE HISTORY

A 32 years old lady who delivered 6 months back a healthy baby presented with fullness in her abdomen with no complaint of pain. She was having no other complaint and thought it was due to post pregnancy phase. On examination there was a single large parietal wall lump around umbilicus 20x 18 cm and overlying skin was essentially normal. The margins of lump were well defined and surface was smooth, and consistency was firm to hard. USG showed a large mass lesion. CECT was suggestive of large parietal wall tumour without involvement of intra abdominal organs. USG guided core needle biopsy was suggestive of aggressive fibromatosis without any evidence of malignancy. After PAC fitness wide local excision of tumour and reconstruction of abdominal wall done with component separation and mesh hernioplasty. After 36 months of follow up patient is doing fine.

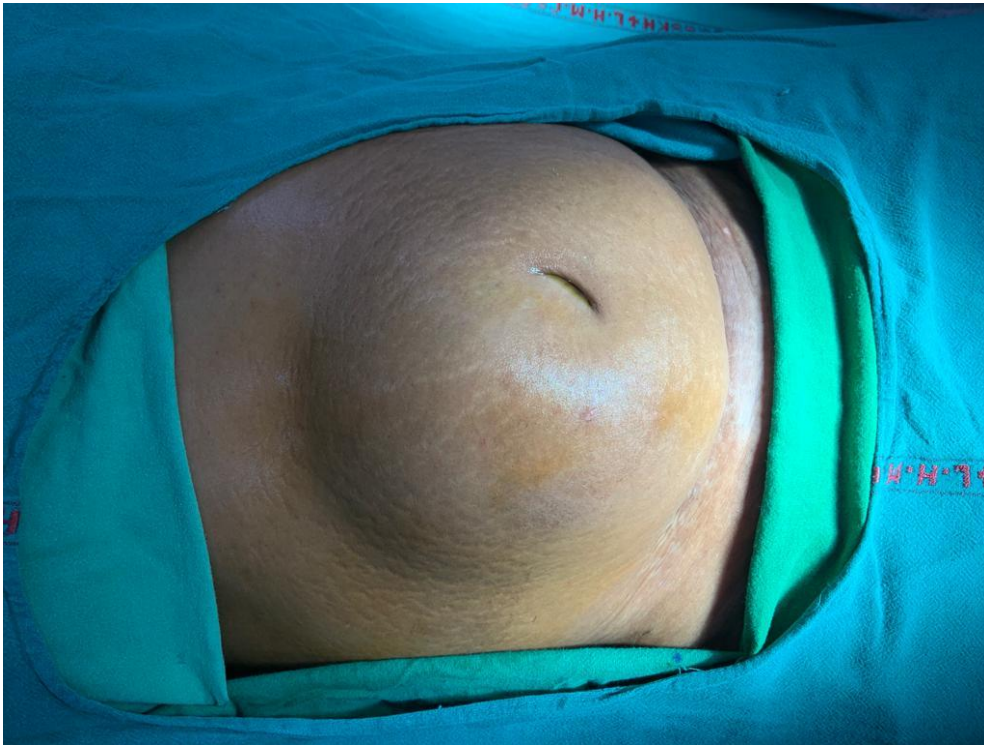

Image 1- Preoperative

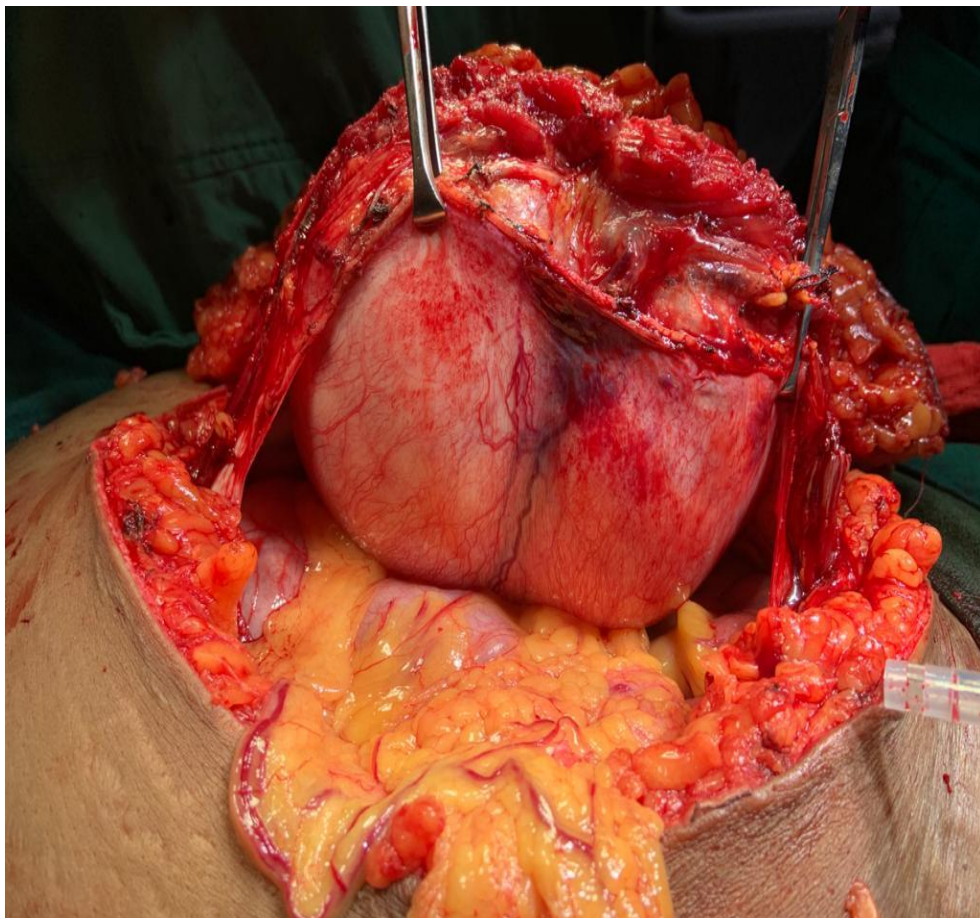


Image 2- Intraoperative

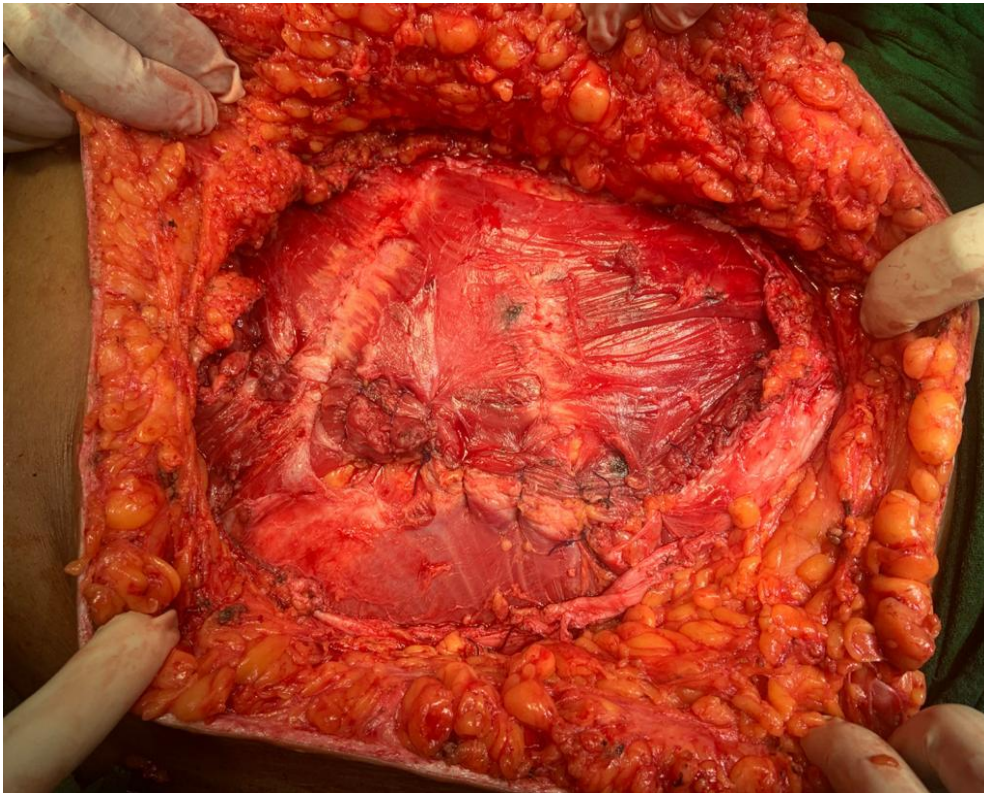


Image 3- Closure after component separation

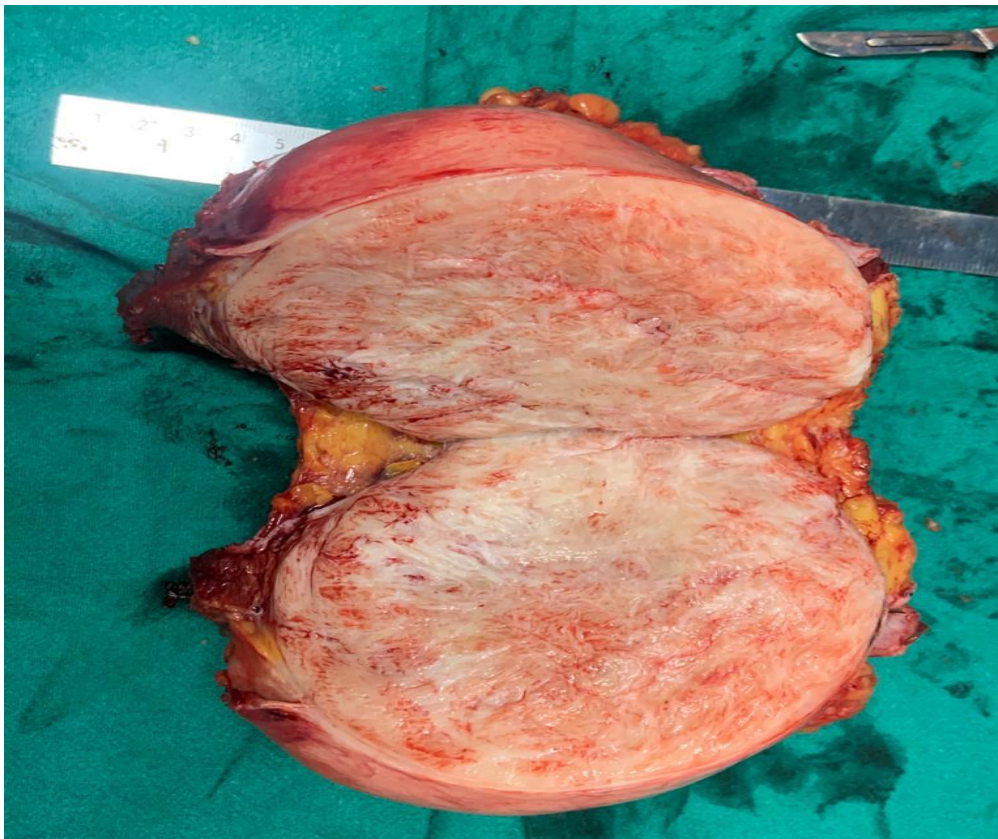

Image 4- Specimen

DISCUSSION

Desmoid tumors constitutes a soft tissue mass which can arise from any part of body connective tissue like muscle, fascia or aponeurosis. Two clinicopathological entities exist: 1) sporadic desmoid tumor (85-90%) 2) Associated with germline mutation of APC gene (10-15%). Beta catenin regulates cell adhesions and cell transcription (AL Jazrawe, M. *et al.*, 2015).

A lot of research has been done in past decades and demonstrated that desmoid tumors are driven by alteration of the Wnt/APC/beta catenin pathways. Sporadic desmoid tumors have shown somatic mutation of CTNNB1 and almost one third of these tumors are misdiagnosed and second pathological opinion is therefore of paramount importance (Panel, N. *et al.*, 2017).

MRI is most appropriate imaging tool for better characterization of the initial extension of tumor and later on to monitor the outcome specially in extremity desmoids and CECT for abdominal wall tumors. Image guided core needle biopsy is required to formally diagnose these tumors. Histologically these tumors are composed of monoclonal spindle shaped cells separated by an abundant collagenous matrix and nodular fasciitis and low grade fibromyxoid sarcomas are usual differential diagnosis by pathologists (AL Jazrawe, M. *et al.*, 2015).

A large retrospective study has shown spontaneous regression after pregnancies in 10% cases, documented progression after wait and see in 60% cases, failure of medical treatment in 10% and risk of relapse after surgery in 13% cases. Surgery is no longer a mainstay of treatment as a significant number of retrospective studies propose safety of wait and watch policy in sporadic abdominal wall desmoid tumor (Fiore, M. *et al.*, 2014).

The heterogeneity of the biological behaviour of desmoids range from long periods of stable disease to spontaneous regression and this warrants need for individualized treatment and there is strong need to understand in order to categorise them in tumors that may stabilize and those that may progress. Watchful waiting can be a good alternative to avoid morbidity associated with surgery in asymptomatic or minimally

symptomatic patients (AL Jazrawe, M. *et al.*, 2015; & Kasper, B. *et al.*, 2011).

NSAIDs and Imatinib used for a longer time can shrink the tumor. Some hormones have shown to increase desmoid tumors so, antiestrogens and prostaglandins are used. Doxorubicin, Dacarbazine and Carboplatin are chemotherapy agents. Noval molecular targeted therapies receptor kinase inhibitors Gleevec and sorafenib are used as kinases are regulators of cell growth, differentiation and motility (Panel, N. *et al.*, 2017).

CONCLUSION

Desmoid fibromatosis is a rare soft neoplasm with a high incidence of local recurrence. Imaging plays an important role in diagnosis as well as management. Desmoid tumours were typically managed with surgery in past but recent advances in molecular cytogenetics and tumour biology have led to a paradigm shift in the management of this condition with optimizing local tumor control and preserving quality of life and strongly recommend multidisciplinary assessment and multimodality treatment for favourable outcome.

REFERENCES

1. Shield, C.J., Winter, D.C., Kirwan, W.O., & Redmond, H.P. (2001). Desmoid tumor. *Eur J Surg Oncol.* 27, 701-6
2. Kumar, V., Khanna, S., Khanna, A.K., & Khanna, R. (2009). Desmoid tumors: Experience of 32 cases and review of literature. *Indian J Cancer.* 46(1), 34-39
3. AL Jazrawe, M., Au, M., & Alman, B. (2015). Optimal therapy for desmoid tumor: current options and challenges for the future. *Expert Rev Anticancer Ther.* 15(12), 1443-58
4. Kasper, B., Strobd, P., & Hohenberger, P. (2011). Desmoid tumor: clinical features and treatment options for advanced disease. *Oncologist.* 16(5), 682-693
5. Panel, N., Chibon, F., & Salas, S. (2017). Adult desmoid tumors: biology, management and ongoing trials. *Curr Opin Oncol.* 29(4), 268-274
6. Fiore, M., Cappola, S., Cannell, A.J. (2014). Desmoid type fibromatosis and pregnancies. A multiinstitutional analysis of recurrence. *Ann Surg* 259, 973-978.