

A Rare Esophageal Atresia in a Trisomy 21 Newborn

Article History
<p>Received: 21.11.2020 Revision: 27.12.2020 Accepted: 08.01.2020 Published: 20.01.2020 Plagiarism check - Plagscan</p>
Author Details
<p>Narjes Hazimeh¹, Bassem Abou Merhi¹, Kamal Kanso¹, Fadi Iskandarani², Fatima Ahmad¹, Mohamad Cheet¹, Fawzia Medlej¹ and Haidar Houmani¹</p>
Authors Affiliations
<p>¹Faculty of Medical Sciences, Pediatrics Department, Lebanese University, Beirut, Lebanon</p> <p>²Faculty of Medical Sciences, Pediatrics Surgery Department, Lebanese University, Beirut, Lebanon</p>
Corresponding Author*
<p>Bassem Abou Merhi</p>
How to Cite the Article:
<p>Narjes Hazimeh, Bassem Abou Merhi, Kamal Kanso, Fadi Iskandarani, Fatima Ahmad, Mohamad Cheet, Fawzia Medlej and Haidar Houmani (2021). A Rare Esophageal Atresia in a Trisomy 21 Newborn. <i>IAR J Med & Surg Res</i>, 2(1),6-8.</p>
<p>Copyright @ 2021: This is an open-access article distributed under the terms of the Creative Commons Attribution license which permits unrestricted use, distribution, and reproduction in any medium for non commercial use (NonCommercial, or CC-BY-NC) provided the original author and source are credited.</p>

Abstract:

Keywords:

INTRODUCTION:

Down syndrome is the most common chromosomal abnormality encountered in humans, and it is caused by the presence of a third copy of chromosome 21, whether whole or merely a portion (Jiang, J. *et al.*, 2013). Although structural defects may occur involving any part of the gastrointestinal tract starting from the mouth reaching the anus, the frequency of many conditions in Down syndrome will be similar to that in other children (co- morbidities?). Some of the conditions encountered more frequently in patients with Down syndrome are atresia (esophageal, duodenal, or small bowel), annular pancreas causing small bowel obstruction, imperforate anus, and Hirschsprung disease (Buchin, P. J. *et al.*, 1986). However, esophageal atresia (EA) with or without tracheoesophageal fistula (TEF) remains the most common congenital anomaly of the esophagus encountered in neonates (Spitz, L. 2007; & Mortell, A. E., & Azizkhan, R. G. 2009, February), and it has been associated, in 5.5% of cases, to chromosomal anomalies such as trisomy of chromosomes 13, 14 and 18 (Pinheiro, P. F. M. *et al.*, 2012).

CASE DESCRIPTION:

A premature 33 week of gestational age female neonate born by C-section due to polyhydramnios to a 41 year old G1P1A0 mother. The girl was admitted to the intensive care of neonates unit (ICN) for a history of respiratory distress (tachypnea with mild subcostal retractions) associated with drooling and hypersalivation. On physical exam, she had multiple dysmorphic features of Down syndrome including flat facies, short and web neck, protruding tongue, almond shaped eyes, wide nasal bridge, and simian creases. The abdomen was flat.

She was kept nil per os (NPO), and a trial of nasogastric tube (NGT) insertion was attempted. However, deep NGT insertion failed. Chest and abdomen x-rays were done and showed absence of gas in the digestive tract with bulking of the NGT at the level of the neck (figure 1). Esophageal atresia type A was suspected (figure 2).

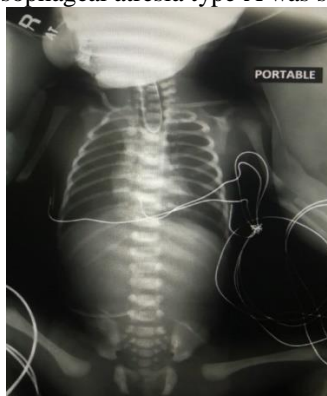


Figure 1: KUB showing coiled NGT in upper esophagus



Figure 2: Esophageal atresia Type A without Tracheoesophageal fistula

An abdominal ultrasound was normal. Pediatric surgery team was consulted, and an open esophagostomy with gastrostomy was done. Few days later, after a trial of feeding per gastrostomy, the baby's condition deteriorated. She developed a sero-sanguinous secretion from the gastrostomy. The abdomen was tense, the skin was mottled, and a respiratory support was needed. After stabilization, an urgent abdominal x-ray was done showing minimal gas distribution in the digestive tract with abundant gas in the abdomen suggestive of pneumoperitoneum (football sign) as shown in figure 3. A perforation was suspected.

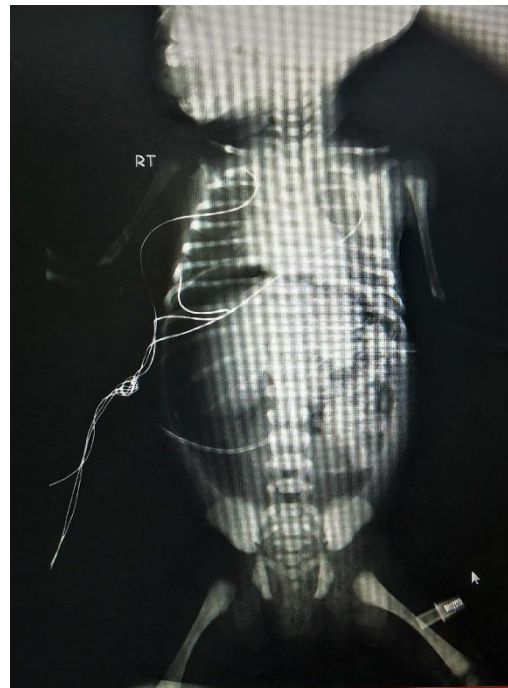

Figure 3: KUB showing pneumoperitoneum

An urgent laparotomy was done. Multiple gastric perforations were identified with a small bowel perforation. The girl was kept NPO for 21 days on broad spectrum antibiotics and total parental nutrition (TPN). During hospitalization, she was diagnosed to have associated hypothyroidism and appropriate treatment was started (Levothyroxine). Cardiac ultrasound was normal. Twenty one days later, a trial of feeding per gastrostomy was successful. The baby was discharged home on gastrostomy feeding and L-Thyroxin with follow up for total repair. In conclusion, this is a case of late preterm girl with trisomy 21 associated with esophageal atresia type A complicated by gastric and small bowel perforation.

DISCUSSION:

Esophageal atresia, with or without TEF, is a relatively rare condition. This complex anomaly is still a challenging problem in pediatric surgery despite all medical advances (Spitz, L. 2007; & Mortell, A. E., & Azizkhan, R. G. 2009, February). The overall incidence of EA/TEF ranges from one in every 2500 to 4500 live births (Spitz, L. 2007). According to Cross and Vogt, EA is classified according to the location of the atresia and the presence of any associated fistula to the trachea. According to Pinheiro PFM *et al.*, the type A (isolated esophageal atresia without any TEF), as in our case, accounts for only 8% of all esophageal atresia types. It ranks in the second place of EA types (fig 4) (Pinheiro, P. F. M. *et al.*, 2012). Thus, this type is not very common.

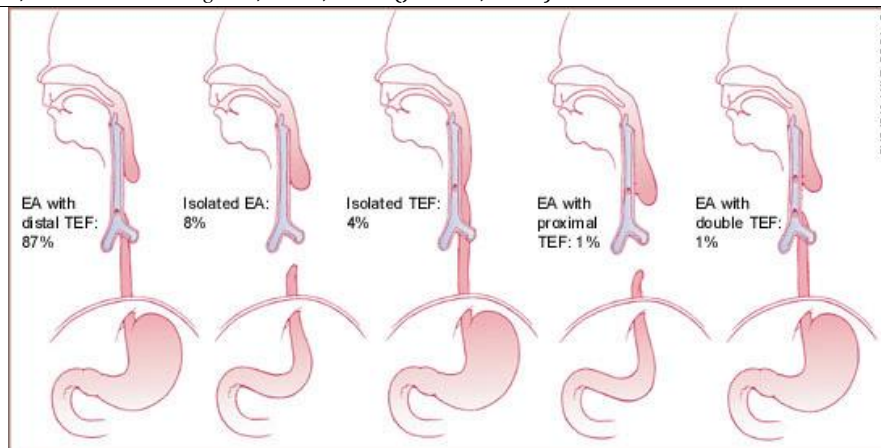


Figure 4: Frequencies of the various esophageal atresia types

The association between EA and chromosomal anomalies is common. However, in the case of Down syndrome, BERMUDEZ *et al.*, showed that 6.25% of cases develop digestive tract malformations. Only 2 patients out of 1,207 (0.2%) developed EA similar to what was reported worldwide; varying between 0.3 to 0.8% of patients with Down syndrome (Bermudez, B. E. *et al.*, 2019). Thus, our case is a rare condition encountered in Down syndrome patients. It should be mentioned that Li *et al.*, reported EA to be associated with a mortality rate of 18.1% during the first weeks of life, whether operated or not (Bermudez, B. E. *et al.*, 2019). It can be also associated with postoperative complications, such as leak and stenosis of the anastomosis, gastroesophageal reflux (GER), esophageal dysmotility, fistula recurrence, scoliosis, deformities of the thoracic wall, and respiratory disorders. According to Pinheiro PFM *et al.*, the feeding postoperatively per tube should be started slowly and initiated 48 hours following the surgery (Pinheiro, P. F. M. *et al.*, 2012). In our case, despite a progressive feeding approach, a perforation of the stomach and small bowel developed. This condition can be attributed to neonatal sepsis. That's why, after broad spectrum of antibiotics, the patient improved. Furthermore, after surgery, the leak from the esophagus might occur in 15-20% of cases (Pinheiro, P. F. M. *et al.*, 2012). Leaks result from the friability of lower segment, ischemia of the esophageal ends, excessive anastomotic tension, sepsis, poor suturing techniques, the type of suture, excessive mobilization of the distal pouch, and increased gap length (Upadhyaya, V. D. *et al.*, 2007). However, a small bowel perforation is not as common as other complications? The highlight in our case is the type A of esophageal atresia that is usually uncommon especially in association with Down syndrome patients with the unusual complication by a small bowel perforation.

CONCLUSION:

Complete Esophageal atresia without TEF (type A) is a rare gastrointestinal malformation, commonly seen in trisomy 13, 14 and 18. However, although rare, it might occur in patients with Down syndrome leading to unusual life-threatening complications.

REFERENCES:

- Bermudez, B. E., de Oliveira, C. M., de Lima Cat, M. N., Magdalena, N. I., & Celli, A. (2019). Gastrointestinal disorders in Down syndrome. *American Journal of Medical Genetics Part A*, 179(8), 1426-1431. Doi: 10.1002/ajmg.a.61258. Epub 2019 Jun 10. PMID: 31183986.
- Buchin, P. J., Levy, J. S., & Schullinger, J. N. (1986). Down's syndrome and the gastrointestinal tract. *Journal of clinical gastroenterology*, 8(2), 111-114. Doi: 10.1097/00004836-198604000-00002. PMID: 2943789.
- Jiang, J., Jing, Y., Cost, G. J., Chiang, J. C., Kolpa, H. J., Cotton, A. M., ... & Pearl, J. R. (2013). Translating dosage compensation to trisomy 21. *Nature*, 500(7462), 296-300. Doi: 10.1038/nature12394. Epub 2013 Jul 17. PMID: 23863942; PMCID: PMC3848249.
- Mortell, A. E., & Azizkhan, R. G. (2009, February). Esophageal atresia repair with thoracotomy: the Cincinnati contemporary experience. In *Seminars in pediatric surgery* (Vol. 18, No. 1, pp. 12-19). WB Saunders. doi: 10.1053/j.sempedsurg.2008.10.003. PMID: 19103416.
- Pinheiro, P. F. M., e Silva, A. C. S., & Pereira, R. M. (2012). Current knowledge on esophageal atresia. *World journal of gastroenterology: WJG*, 18(28), 3662. Doi: 10.3748/wjg.v18.i28.3662. PMID: 22851858; PMCID: PMC3406418.
- Spitz, L. (2007). Oesophageal atresia. *Orphanet journal of rare diseases*. 2(1), 24.
- Upadhyaya, V. D., Gangopadhyaya, A. N., Gupta, D. K., Sharma, S. P., Kumar, V., Pandey, A., & Upadhyaya, A. D. (2007). Prognosis of congenital tracheoesophageal fistula with esophageal atresia on the basis of gap length. *Pediatric surgery international*, 23(8), 767-771. doi: 10.1007/s00383-007-1964-0. Epub 2007 Jun 20. PMID: 17579871.