

Role of Ultrasonography to Differentiate Simple and Complicated Appendicitis in Children

Jahangir Alam^{*1}, Hasan Ullah², KM Zafrul Hossain³, Saiful islam⁴, Arifur Rahaman⁵, Niaz Anam Nilave⁶

¹ Department of Paediatric Surgery, Institute of Woman and Child Health, Dhaka

² Department of Paediatric Surgery, Institute of applied health sciences (IAHS),

³ Department of Paediatric Surgery, TMSS Medical college, Bogura

⁴ Department of Surgery, Enam medical college & Hospital, Dhaka

⁵ Department of Paediatric Surgery, Central Medical College & Hospital, Cumilla

⁶ Department of Paediatric Surgery, Dinajpur Medical College Hospital

ABSTRACT

Background: Appendicitis remains one of the most common surgical conditions in children, with surgical appendectomy being the standard treatment. However, the complications from surgery prompt interest in nonoperative management and accurate diagnostic methods. **Objective:** This study aims to evaluate the role of ultrasonography in differentiating simple from complicated appendicitis in children, improving diagnostic accuracy and reducing unnecessary surgery. **Methods:** A prospective observational study was conducted at the Paediatric Surgery Department, Mymensingh Medical College Hospital, from January 2021 to June 2022. The study involved 100 children diagnosed with acute appendicitis via ultrasound. Inclusion and exclusion criteria were followed, and informed consent was obtained from all participants. The clinical data, ultrasonographic findings, and histopathological results were collected, and diagnostic accuracy was evaluated using sensitivity, specificity, and predictive values. **Results:** Out of 100 patients, 68% were diagnosed with simple appendicitis and 32% with complicated appendicitis by ultrasonography. Histopathological analysis confirmed 42% simple and 58% complicated cases. The mean age was 10.14 ± 4.66 years. The sensitivity of ultrasonography in identifying complicated appendicitis was 44.83%, while its specificity was 85.71%. The positive predictive value (PPV) was 81.25%, and the negative predictive value (NPV) was 52.94%. Statistical analysis revealed a p-value of 0.001, indicating significant differences between the groups. Standard deviation for age was calculated as 4.66, reflecting a spread in patient age distribution. **Conclusion:** Ultrasonography, though useful, should not be relied upon alone to differentiate between simple and complicated appendicitis. A combination of clinical, laboratory, and ultrasonographic findings is essential for optimal diagnosis.

Keywords: Ultrasonography, Appendicitis, Pediatric Surgery, Sensitivity, Specificity

Submitted: 14.03.2025 | Accepted: 16.05.2025 | Published: 31.05.2025

*Corresponding Author:

Dr. Md. Jahangir Alam, Email: dr.jahangir1318@ gmail.com

How to Cite the Article:

Jahangir Alam, Hasan Ullah, KM Zafrul Hossain, Saiful islam, Arifur Rahaman, Niaz Anam Nilave. Role of Ultrasonography to Differentiate Simple and Complicated Appendicitis in Children. IAR J Med Surg Res. 2025;6(2):79–89.

© 2025 IAR Journal of Medicine and Surgery Research, a publication of JMSRP Publisher, Kenya. This is an open access article under the terms of the Creative Commons Attribution license. (<http://creativecommons.org/licenses/by/4.0>). (<https://jmsrp.org/index.php/jmsrp>).

INTRODUCTION

Acute appendicitis remains a predominant abdominal surgical emergency worldwide, particularly in pediatric populations, accounting for the majority of

pediatric emergency surgeries [1]. The accurate diagnosis and effective management of appendicitis, distinguishing between simple and complicated forms, are paramount to ensuring favorable patient outcomes and reducing the rate

of unnecessary interventions such as negative appendectomies. Although the management paradigm has evolved with advancements in imaging and surgical techniques, significant challenges persist, particularly in the early stages of diagnosis, where atypical presentations can confound clinical decision-making. Given the prevalence of appendicitis in children, which peaks between the ages of 9 to 12 years [2], the identification of subtypes—simple appendicitis and complicated appendicitis—remains critical to optimize treatment strategies and prevent the complications associated with misdiagnosis.

Acute appendicitis is characterized by inflammation of the vermiform appendix, and its etiology is often multifactorial, involving obstruction of the appendiceal lumen by fecaliths, lymphoid hyperplasia, or less commonly, tumors [3]. In pediatric patients, appendicitis can develop rapidly, with early perforation being a common complication, particularly in younger children under the age of 5, who are more prone to rapid progression due to anatomical and immune factors [4]. The distinction between simple appendicitis, characterized by uncomplicated inflammation, and complicated appendicitis, which includes perforation, abscess formation, and phlegmon, significantly impacts management strategies [5]. While early surgical intervention is generally recommended for uncomplicated appendicitis, the management of complicated appendicitis often involves a combination of initial nonoperative treatment and subsequent surgical intervention, tailored to the patient's clinical progression [6].

The diagnostic landscape of appendicitis has significantly improved with the advent of advanced imaging techniques, notably ultrasonography, computed tomography (CT), and magnetic resonance imaging (MRI) [7]. However, each imaging modality comes with distinct advantages and limitations, making the choice of method pivotal in pediatric settings. Ultrasound, in particular, has emerged as the first-line imaging modality in children due to its non-invasive nature, lack of ionizing radiation, and high diagnostic accuracy, especially when performed by experienced operators [8]. Studies have demonstrated that ultrasound boasts a specificity greater than 98% in diagnosing acute appendicitis, making it a highly reliable tool for this purpose [9]. Furthermore, recent advancements in ultrasonographic technology have enabled the differentiation between simple and complicated appendicitis, highlighting its potential as a

valuable tool in pediatric clinical settings. The sonographic appearance of simple appendicitis is typically characterized by the identification of a dilated, noncompressible appendix with a diameter greater than 6mm, without evidence of complicated features such as free fluid, phlegmon, or abscess formation [10]. In contrast, complicated appendicitis presents with more complex findings, such as the loss of the echogenic submucosal layer, complex peri appendiceal fluid, and thickening of the appendiceal wall, all indicative of a perforated or abscessed appendix [11]. These specific findings, when identified on ultrasound, can aid in the accurate differentiation of simple from complicated appendicitis, thus guiding management decisions and improving patient outcomes.

Despite the diagnostic accuracy of ultrasound, clinical challenges persist, particularly in cases where the clinical presentation is ambiguous or where symptoms overlap with other abdominal conditions. Studies have shown that approximately 20-30% of children diagnosed with appendicitis may exhibit atypical presentations that mimic other conditions, leading to diagnostic uncertainty [12]. This has profound implications, as unnecessary appendectomies—negative appendectomies—carry both psychological and physical burdens for patients, including surgical complications, longer recovery times, and increased healthcare costs. One of the key advantages of ultrasound is its ability to reduce the negative appendectomy rate, as it provides additional diagnostic confirmation of appendicitis, particularly in equivocal cases that might otherwise require more invasive procedures such as exploratory laparotomy or CT scans [13]. The ability to perform real-time, dynamic evaluations with ultrasound provides clinicians with the opportunity to observe changes in the appendix during the examination, improving diagnostic certainty and minimizing unnecessary procedures. Recent studies have demonstrated that the addition of ultrasound in cases with equivocal CT findings can significantly decrease the rate of negative appendectomies. A study conducted by Kelly *et al.* found that the use of ultrasound in conjunction with clinical examination reduced the negative appendectomy rate by 20%, highlighting the importance of ultrasound in confirming diagnoses and potentially avoiding unnecessary surgeries [14]. Additionally, in cases where the diagnosis remains unclear, ultrasound provides a non-invasive method of monitoring the progression of symptoms, enabling clinicians to reassess their approach

without resorting to high-cost or high-risk interventions.

Although ultrasound offers numerous advantages in diagnosing pediatric appendicitis, several limitations remain. The accuracy of ultrasound in diagnosing complicated appendicitis can be influenced by factors such as the operator's skill level, the patient's body habitus, and the timing of the examination relative to the onset of symptoms. The presence of bowel gas, particularly in children with significant distension or obesity, can hinder the visualization of the appendix, resulting in non-diagnostic images [15]. Furthermore, while ultrasound can identify complications such as perforation and abscess formation, it may not always provide sufficient details on the extent of the disease, such as the exact location of an abscess or the presence of other associated intra-abdominal pathologies. In some cases, a negative ultrasound result does not definitively rule out appendicitis, especially in patients with a high clinical suspicion. Therefore, ultrasound should be considered as part of a multimodal approach, integrating clinical findings, laboratory tests, and other imaging techniques to achieve the most accurate diagnosis. It is essential to maintain a high level of clinical suspicion and to utilize ultrasound in conjunction with other diagnostic modalities, especially when complex or atypical cases are encountered.

Aims and Objective

The primary aim of this study is to assess the role of ultrasonography in differentiating between simple and complicated appendicitis in children. Specific objectives include analyzing demographic characteristics, performing preoperative ultrasound, conducting histopathological examination of resected appendices, and evaluating the diagnostic accuracy of ultrasonography using sensitivity, specificity, PPV, and NPV.

MATERIALS AND METHODS

Study Design

This study was a prospective observational study conducted at the Department of Pediatric Surgery, Mymensingh Medical College Hospital, Mymensingh, Bangladesh. The study spanned over 18 months, from January 2021 to June 2022. Patients aged up to 18 years with an ultrasonographic ally confirmed diagnosis of acute appendicitis who underwent appendectomy were included in the study. The primary objective was to assess

the role of ultrasonography in differentiating between simple and complicated appendicitis in children. The study employed purposive sampling, ensuring the inclusion of relevant cases based on predefined inclusion and exclusion criteria.

Inclusion Criteria

The study included patients aged up to 18 years who were diagnosed with acute appendicitis based on ultrasonographic findings. Only those who underwent appendectomy at the Paediatric Surgery Department, Mymensingh Medical College Hospital, Mymensingh, were included. Patients with clear ultrasonographic diagnoses of simple or complicated appendicitis were considered eligible for this study. Written informed consent was obtained from the patients' guardians prior to participation in the study, ensuring their willingness and understanding.

Exclusion Criteria

Severely ill patients with appendicitis who were not fit for surgery were excluded from the study. Additionally, patients with co-existing comorbidities such as intestinal tuberculosis, enteric fever, and Crohn's disease were excluded as these conditions could confound the diagnosis of appendicitis. Patients with incomplete data, including missing ultrasonography, surgical, or histopathology reports, were also excluded. These exclusion criteria ensured that the study focused solely on those who had a definitive diagnosis and underwent standard treatment for appendicitis.

Data Collection

Data collection involved gathering baseline patient characteristics (e.g., age, sex), ultrasonographic findings, peroperative surgical details, and histopathology results for each participant. A standardized form was used for data recording to ensure consistency and accuracy. Ultrasonographic reports were classified into simple or complicated appendicitis based on specific findings. Data were cross-checked for completeness, and any missing or inconsistent information was addressed before final analysis. The collected data were stored securely for further analysis.

Data Analysis

Data analysis was conducted using SPSS version 26.0 (Statistical Package for the Social Sciences) software.

Descriptive statistics, such as means, standard deviations, and frequencies, were calculated for demographic and clinical variables. Sensitivity, specificity, positive predictive value (PPV), negative predictive value (NPV), and diagnostic accuracy were calculated to evaluate the performance of ultrasonography in differentiating simple from complicated appendicitis. The results were presented using tables and graphs, and statistical significance was evaluated to understand the relationship between ultrasonographic findings and histopathological outcomes.

Procedure

This study was conducted at the Paediatric Surgery Department of Mymensingh Medical College Hospital from January 2021 to June 2022. Children aged up to 18 years with a clinical suspicion of appendicitis who presented to the hospital during the study period were assessed for eligibility. Following initial clinical examination, patients who met the inclusion criteria and had ultrasonographic confirmation of acute appendicitis were enrolled in the study. An experienced sonographer

performed all ultrasound examinations, which were classified as indicative of either simple or complicated appendicitis based on predefined ultrasonographic criteria. Simple appendicitis was diagnosed in cases where the appendix was dilated, noncompressible, and lacked evidence of perforation, phlegmon, or abscess. Complicated appendicitis was diagnosed when ultrasonographic findings such as peri-appendiceal fluid greater than 1 cm, extraluminal gas, or loss of the submucosal layer were observed. The clinical condition of the patients was closely monitored, and all underwent appendectomy as per the standard procedure. The resected appendix was sent for histopathological examination to confirm the diagnosis. The histopathology reports were used as the gold standard to classify patients into simple or complicated appendicitis. The data collected were analyzed using statistical software to calculate the sensitivity, specificity, PPV, and NPV of ultrasonography in differentiating between the two forms of appendicitis. The study aimed to validate the role of ultrasound as a reliable diagnostic tool in pediatric appendicitis.

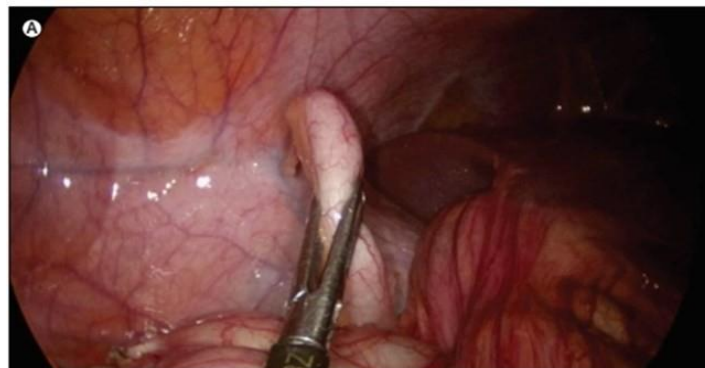

Figure 1: Macroscopically Normal Appendix

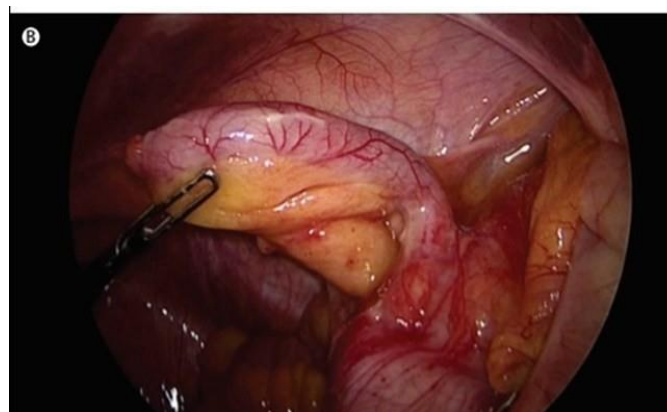


Figure 2: Simple Inflamed Appendicitis

Ethical Considerations

Ethical approval for the study was obtained from the institutional review board of Mymensingh Medical College. Written informed consent was obtained from the parents or guardians of the pediatric patients before participation in the study. Confidentiality and anonymity were maintained throughout the research process. Patients had the right to withdraw from the study at any stage without any adverse consequences. The study adhered to ethical guidelines, ensuring that it caused no harm to the participants.

RESULTS

This prospective type of observational study was conducted on 100 patients aged up to 18 years with acute appendicitis who were admitted at Paediatric Surgery Department and ultrasonographic confirmed diagnosis of acute appendicitis and undergoes appendectomy in the Paediatric Surgery Department, Mymensingh Medical College Hospital, Mymensingh. For all eligible patients, data regarding baseline characteristics (i.e. age, sex), ultrasonography, surgery and histopathology was collected to a standardized form. The observations were noted in the following tables.

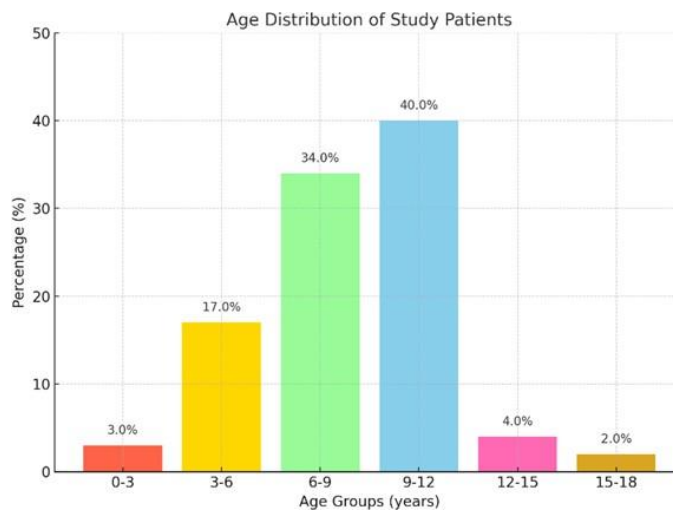


Figure 3: Age Distribution of the Study Patients (n=100)

Figure 3 shows age of the study population with mean age 10.14±4.66 years. Maximum 40% of patients belonged to 9-12 years followed by 34% of patients aged 6-9 years.

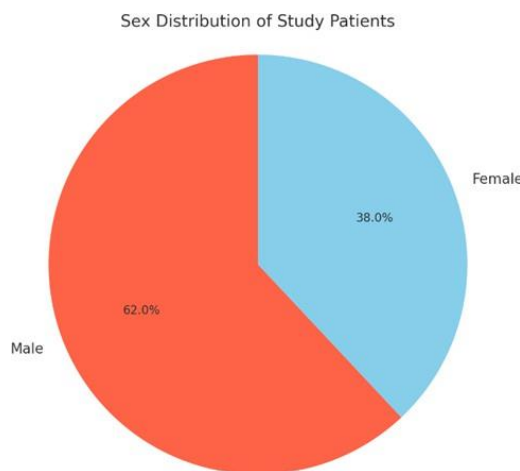


Figure 4: Sex Distribution of the Study Patients (n=100)

Figure 4 showed the sex distribution of the study patients. Maximum patients 62% were male and 38% patients were female. The male: female ratio was 1.6:1.

Table 1: Distribution of Symptoms of Acute Appendicitis (n=100)

Symptoms	Number of patients	Percentage (%)
Right lower abdominal pain	100	100.0
Nausea	78	78.0
Vomiting	71	71.0
Fever	65	65.0
Dysuria	14	14.0
Diarrhea	5	5.0

100% patients had right lower abdominal pain, 78% patients had nausea, vomiting in 71.0% cases, 65% patients had fever, 14% patients had dysuria and diarrhea in 5% cases.

Table 2: Distribution of Signs of Acute Appendicitis (n=100)

Signs	Number of patients	Percentage (%)
RIF. Tenderness	100	100.0
Tachycardia	72	72.0
Rebound tenderness	64	64.0
Cough sign	21	21.0

Regarding signs of acute appendicitis RIF tenderness in 100% cases, tachycardia in 72% cases, rebound tenderness in 64% cases, cough sign had 21%.

Table 3: Preoperative Findings of Simple Appendicitis (n=44)

Preoperative findings	Number of patients	Percentage (%)
Signs of congestion, an increased diameter.	44	100
Color change (red)	44	100
Exudates	14	31.81

Out of 44 patients with simple appendicitis, 44(100%) patients had sign of congestion and an increased diameter, 44(100%) patients were color change (red), and 14 (31.81%) patients had exudates.

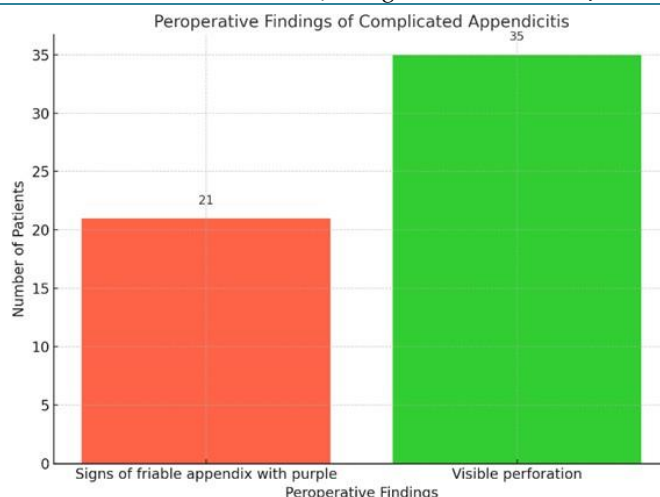


Figure 5: Preoperative Findings of Complicated Appendicitis (n=56)

Out of 56 patients of complicated appendicitis, maximum 35(62.5%) patients had visible perforation and/or abscess formation, and 21(37.5%) patients had signs of friable appendix with purple or black color change.

Table 5: Ultrasonographic Criteria for Simple Appendicitis (n=68)

Sonographic findings of simple appendicitis	Number patients	Percentage (%)
Incompressible appendix	64	94.11
Hyperemic appendiceal wall	37	54.41
Infiltration of peri-appendiceal fat	45	66.17
Outer diameter ≥ 6 mm	66	97.05
No signs of perforation or abscess/phlegmon	68	100.0

According to Ultrasonography reports, 68(100.0%) patients were diagnosed with simple appendicitis. Among them we found no signs of perforation or abscess/phlegmon in 68(100.0%) patients, 66(97.05%) patients had outer diameter ≥ 6 mm, 45(66.17%) patients had hyperaemic appendiceal wall and 37(54.41%) patients had infiltration of peri-appendiceal fat. All are indicative of simple appendicitis (test negative).

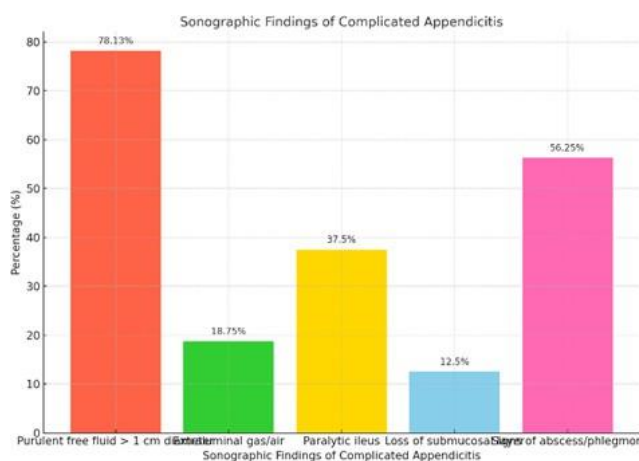


Figure 6: Ultrasonographic Criteria for Complicated Appendicitis (n=32)

According to Ultrasonography reports, 32(100.0%) patients were diagnosed with simple appendicitis. Among them we found purulent free fluid > 1 cm diameter in 25(78.13%) patients, Signs of abscess/phlegmon in 18(56.25%) cases, Paralytic ileus in 12(37.5%) cases, Extraluminal gas/air in 6(18.75%) cases

and 4(12.5%) patients had Loss of submucosal layer. The most frequent reason for a complicated ultrasonography result was the presence of purulent free fluid >1cm diameter. All of them are indicative of complicated appendicitis (test positive).

Table 6: Comparison of Ultrasonography (US) with Histopathology (n=100)

USG findings	Histopathological findings		Total (n=100)
	Complicated (n=58)	Simple (n=42)	
Complicated	26 (44.8%) (TP)	6 (14.3%) (FP)	32 (32.0%)
Simple	32 (55.2%) (FN)	36 (83.7%) (TN)	68 (68.0%)
Total	58 (100.0%)	42 (100.0%)	100 (100.0%)

Table 6 displays the 2x2 contingency table. According to Ultrasonography reports, 32(32%) patients were diagnosed with complicated appendicitis (test positive) and 68(68%) patients with simple appendicitis

(test negative). Histopathologic ally (gold standard) 58(58%) patients were diagnosed with complicated appendicitis and 42(42%) with simple appendicitis.

Table 7: Diagnostic Performance

Statistic	Value	95% CI
Sensitivity	44.83%	31.74% to 58.46%
Specificity	85.71%	71.46% to 94.57%
PPV	81.25%	66.20% to 90.55%
NPV	52.94%	46.38% to 59.40%
Accuracy	62.00%	51.75% to 71.52%

Table 7 displays the 2x2 contingency table derived from these results. Accordingly, a sensitivity of 44.83% (95% CI 31.74–58.46%) and a specificity of 85.71% (95% CI 71.46–94.57%) was found for the accuracy of ultrasonography in differentiating complicated from simple appendicitis. 81.25% (95% CI 66.2–90.55%) of patients with an ultrasonography report indicative of complicated appendicitis were diagnosed with complicated appendicitis according to our gold standard (PPV). Of those patients with an ultrasonography report indicative of simple appendicitis, 52.94% (95% CI 46.4–59.40%) were diagnosed with simple appendicitis according to our gold standard (NPV).

DISCUSSION

In this study, we observed a male-to-female ratio of 1.6:1, with males more commonly affected than females. This finding aligns with previous studies such as Blok *et al.*, who also reported a higher incidence of appendicitis in

males [15]. The male predominance in appendicitis has been attributed to various factors, including differences in abdominal anatomy, immune responses, and perhaps even behavioral factors. The highest number of cases in our study occurred in the 9-12 years age group, with 40% of the patients in this category, followed by the 6-9 years age group (34%). This age distribution is consistent with the findings of Blok *et al.*, who found that the highest incidence of appendicitis in children occurred in the same age groups [15]. The age-related trends in appendicitis are important for clinicians, as the preadolescent years are often characterized by an increased incidence due to anatomical factors such as the size and position of the appendix.

Clinical Presentation and Symptoms

Acute appendicitis in children typically presents with right lower abdominal pain, nausea, vomiting, fever, and sometimes dysuria or diarrhea. In this study, 100% of

patients presented with right lower abdominal pain, 78% had nausea, 71% had vomiting, 65% had fever, 14% had dysuria, and 5% had diarrhea. These findings are consistent with Pogorelić *et al.*, who reported similar symptoms in pediatric patients, where nausea and vomiting were the most common signs, followed by right lower abdominal pain [16]. Kim *et al.* also found that tenderness in the right iliac fossa (RIF) was present in all patients (100%) and that vomiting was observed in 91% of cases, which is consistent with our study [17]. Although right lower abdominal pain is the most common symptom in appendicitis, the occurrence of additional symptoms such as nausea, vomiting, fever, and, in some cases, dysuria or diarrhea, further complicates the diagnosis. Our study also highlights the importance of monitoring a combination of symptoms to avoid misdiagnosis, particularly in younger children who may not express their symptoms clearly.

Peroperative Findings and Histopathology

In this study, peroperative findings of simple appendicitis were noted in 44 patients, with histopathological confirmation of simple appendicitis in 42 (95.5%) cases. The remaining 2 patients (4.5%) were found to have complicated appendicitis. Similarly, in 56 patients with peroperative findings of complicated appendicitis, all were confirmed by histopathology as complicated appendicitis. These results show a strong correlation between peroperative findings and histopathological reports, with peroperative assessment playing a crucial role in identifying complicated cases. The rate of complicated appendicitis observed in our study (56%) is in line with the findings of Afuwape *et al.*, who reported a range of 5% to 62% for complicated appendicitis, reflecting variability in appendicitis progression depending on timely diagnosis and treatment [18]. The histopathological confirmation of simple and complicated appendicitis reinforces the accuracy of peroperative findings, providing further evidence that clinical assessment remains vital in identifying cases that require immediate surgical intervention. The findings in this study contribute to the existing literature on appendicitis, supporting the view that the severity of appendicitis is often best evaluated through a combination of clinical, peroperative, and histopathological assessments.

Ultrasonographic Findings and Diagnostic Accuracy

One of the primary objectives of this study was to assess the accuracy of ultrasonography in differentiating between simple and complicated appendicitis. Based on the ultrasonographic findings, 68% of patients were diagnosed with simple appendicitis, and 32% with complicated appendicitis. However, when compared with histopathological findings, 36 patients with ultrasonographic findings of simple appendicitis were confirmed to have simple appendicitis, while 32 were found to have complicated appendicitis (false negatives). Similarly, of the 32 patients diagnosed with complicated appendicitis via ultrasonography, 26 were confirmed as complicated, while 6 were diagnosed with simple appendicitis (false positives). These results demonstrate that ultrasonography has a significant rate of misdiagnosis, particularly in ruling out complicated appendicitis. The sensitivity of ultrasonography in this study was found to be 44.83% (95% CI 31.74–58.46%), while the specificity was 85.71% (95% CI 71.46–94.57%). These values reflect the ability of ultrasonography to identify complicated appendicitis with relatively high specificity, but the sensitivity is low, indicating that many cases of complicated appendicitis go undetected. The positive predictive value (PPV) was 81.25% (95% CI 66.2–90.55%), and the negative predictive value (NPV) was 52.94% (95% CI 46.4–59.40%). These results suggest that ultrasonography is more reliable in identifying true positive cases of complicated appendicitis but is less reliable in ruling out simple appendicitis. The accuracy of ultrasonography in diagnosing complicated appendicitis aligns with findings in other studies. For example, Nijssen *et al.* reported a sensitivity of 46% and specificity of 90% in their study, which is comparable to the present study's findings [19]. Similar to our results, their study found that the PPV and NPV were 84% and 60%, respectively, demonstrating the limitations of ultrasonography in detecting complicated appendicitis. The relatively high specificity of ultrasonography observed in both studies underscores its utility in confirming complicated cases, though its low sensitivity suggests the need for adjunctive diagnostic methods.

Non-Operative Treatment and Diagnostic Challenges

Recent advancements in the management of appendicitis, particularly the exploration of non-operative treatment strategies for simple appendicitis, have increased the importance of accurate preoperative diagnostics. Non-operative management of appendicitis,

including the use of antibiotics, is an increasingly popular strategy for certain patients, particularly those with uncomplicated appendicitis. However, the success of non-operative treatment is heavily dependent on the accurate diagnosis of simple appendicitis. Misdiagnosis of simple appendicitis as complicated appendicitis can result in unnecessary surgery, while misdiagnosing complicated appendicitis as simple appendicitis can lead to treatment failure and increased risk of perforation. Gorter *et al.* and Jumah *et al.* have highlighted the importance of accurate preoperative diagnostics, noting that non-operative treatment failure is often due to the misdiagnosis of simple appendicitis [20, 21]. Emile *et al.* also pointed out that the presence of an appendicolith, a calcified deposit in the appendix, is associated with higher failure rates in non-operative management [22]. In our study, we found that ultrasonography alone was insufficient to accurately differentiate between simple and complicated appendicitis, which raises concerns about its role in guiding non-operative treatment decisions. These findings suggest that a more comprehensive diagnostic approach is necessary, combining ultrasonography with clinical evaluation and laboratory markers such as C-reactive protein (CRP) and white blood cell (WBC) count.

CONCLUSION

Acute appendicitis is a common indication for emergency surgery. Ultrasonography is still a useful tool in the diagnosis of acute appendicitis despite sophisticated investigations like CT abdomen and laparoscopy; thus, reducing the cost of treatment and preventing negative appendectomy. But ultrasonography as a standalone modality is not suitable to predict whether a child suffers from simple or complicated appendicitis. To improve the classification between these two entities other variables such as clinical signs and laboratory data are necessary in conjunction with ultrasonography findings.

Recommendation

Ultrasound is a simple and very effective method for diagnosing acute appendicitis and excludes other abdominal pathology. Non-operative management of ultrasonographic ally detected simple appendicitis is not always indicative.

Acknowledgement

First of all, I thank Almighty Allah, the merciful

and beneficent, for granting me the strength, patience, and energy to complete this thesis. I am deeply grateful to my honorable supervisor, Professor Dr. A.S.M. Lokman Hossain Chowdhury, Professor and Head, Department of Paediatric Surgery, Mymensingh Medical College Hospital, Mymensingh, for his inspiring guidance, constant support, and valuable suggestions. My heartfelt thanks go to all faculty members, colleagues, family, and my beloved wife and daughter for their encouragement and sacrifices.

Funding: No funding sources.

Conflict of interest: None declared.

REFERENCES

1. Aneiros B, Cano I, García A, Yuste P, Ferrero E, Gómez A. Pediatric appendicitis: age does make a difference. *Revista Paulista de Pediatria*. 2019 Jun 19;37:318-24.
2. Lounis Y, Hugo J, Demarche M, Seghaye MC. Influence of age on clinical presentation, diagnosis delay and outcome in pre-school children with acute appendicitis. *BMC pediatrics*. 2020 Dec;20:1-9.
3. Kharbanda AB, Vazquez-Benitez G, Ballard DW, Vinson DR, Chettipally UK, Dehmer SP, Ekstrom H, Rauchwerger AS, McMichael B, Cotton DM, Kene MV. Effect of clinical decision support on diagnostic imaging for pediatric appendicitis: a cluster randomized trial. *JAMA network open*. 2021 Feb 1;4(2):e2036344-.
4. Van Dijk ST, Van Dijk AH, Dijkgraaf MG, Boermeester MA. Meta-analysis of in-hospital delay before surgery as a risk factor for complications in patients with acute appendicitis. *Journal of British Surgery*. 2018 Jul;105(8):933-45.
5. Staab S, Black T, Leonard J, Bruny J, Bajaj L, Grubenhoff JA. Diagnostic accuracy of suspected appendicitis: a comparative analysis of misdiagnosed appendicitis in children. *Pediatric Emergency Care*. 2022 Feb 1;38(2):e690-6.
6. Mushtaq R, Desoky SM, Morello F, Gilbertson-Dahdal D, Gopalakrishnan G, Leetch A, Vedantham S, Kalb B, Martin DR, Udayasankar UK. First-line diagnostic evaluation with MRI of children suspected of having acute appendicitis. *Radiology*. 2019 Apr;291(1):170-7.
7. Serbanescu L, Badiu D, Popescu S, Busu D, Costea AC. The management of tubo-ovarian abscesses associated

- with appendicitis. *Journal of Mind and Medical Sciences.* 2021;8(2):280-5.
8. Moghadam MN, Salarzaei M, Shahraki Z. Diagnostic accuracy of ultrasound in diagnosing acute appendicitis in pregnancy: a systematic review and meta-analysis. *Emergency Radiology.* 2022 Jun;29(3):437-48.
 9. Hao TK, Chung NT, Huy HQ, Linh NT, Xuan NT. Combining ultrasound with a pediatric appendicitis score to distinguish complicated from uncomplicated appendicitis in a pediatric population. *Acta Informatica Medica.* 2020 Jun;28(2):114.
 10. Fawkner-Corbett D, Hayward G, Alkhmees M, Van Den Bruel A, Ordóñez-Mena JM, Holtman GA. Diagnostic accuracy of blood tests of inflammation in paediatric appendicitis: a systematic review and meta-analysis. *BMJ open.* 2022 Nov 1;12(11):e056854.
 11. Wang ZH, Ye J, Wang YS, Liu Y. Diagnostic accuracy of pediatric atypical appendicitis: Three case reports. *Medicine.* 2019 Mar 1;98(13):e15006.
 12. Michelson KA, Reeves SD, Grubenhoff JA, Cruz AT, Chaudhari PP, Dart AH, Finkelstein JA, Bachur RG. Clinical features and preventability of delayed diagnosis of pediatric appendicitis. *JAMA network open.* 2021 Aug 2;4(8):e2122248-.
 13. Riedesel EL, Weber BC, Shore MW, Cartmill RS, Ostlie DJ, Leys CM, Gill KG, Kohler JE. Diagnostic performance of standardized ultrasound protocol for detecting perforation in pediatric appendicitis. *Pediatric Radiology.* 2019 Dec;49:1726-34.
 14. Kelly BS, Bollard SM, Weir A, O'Brien C, Mullen D, Kerin M, McCarthy P. Improving diagnostic accuracy in clinically ambiguous paediatric appendicitis: a retrospective review of ultrasound and pathology findings with focus on the non-visualised appendix. *The British journal of radiology.* 2019 Jan 1;92(1093):20180585.
 15. Blok GC, Veenstra LM, van der Lei J, Berger MY, Holtman GA. Appendicitis in children with acute abdominal pain in primary care, a retrospective cohort study. *Family practice.* 2021 Dec 1;38(6):758-65.
 16. Pogorelić Z, Domjanović J, Jukić M, Poklepović Peričić T. Acute appendicitis in children younger than five years of age: diagnostic challenge for pediatric surgeons. *Surgical infections.* 2020 Apr 1;21(3):239-45.
 17. Kim JR, Suh CH, Yoon HM, Jung AY, Lee JS, Kim JH, Lee JY, Cho YA. Performance of MRI for suspected appendicitis in pediatric patients and negative appendectomy rate: A systematic review and meta-analysis. *Journal of Magnetic Resonance Imaging.* 2018 Mar;47(3):767-78.
 18. Afuwape OO, Ayandipo OO, Soneye O, Fakoya A. Pattern of presentation and outcome of management of acute appendicitis: A 10-year experience. *Journal of Clinical Sciences.* 2018 Oct 1;15(4):171-5.
 19. Nijssen DJ, van Amstel P, van Schuppen J, Eeftinck Schattenkerk LD, Gorter RR, Bakx R. Accuracy of ultrasonography for differentiating between simple and complex appendicitis in children. *Pediatric surgery international.* 2021 Jul;37:843-9.
 20. Gorter RR, van der Lee JH, Heijsters FA, Cense HA, Bakx R, Kneepkens CF, Wijnen MH, van der Steeg AF, In't Hof KH, Offringa M, Heij HA. Outcome of initially nonoperative treatment for acute simple appendicitis in children. *Journal of Pediatric Surgery.* 2018 Sep 1;53(9):1849-54.
 21. Jumah S, Wester T. Non-operative management of acute appendicitis in children. *Pediatric Surgery International.* 2022 Nov 28;39(1):11.
 22. Emile SH, Sakr A, Shalaby M, Elfeki H. Efficacy and safety of non-operative management of uncomplicated acute appendicitis compared to appendectomy: an umbrella review of systematic reviews and meta-analyses. *World Journal of Surgery.* 2022 May;46(5):1022-38.