IAR Journal of Medicine and Surgery Research
https://doi.org/10.47310/iarjmsr.2025.v06i01.0163
Vol. 6, No. 1, 2025

ISSN (Print): 2709-1899
ISSN (Online): 2709-1902

ARTICLE

Role of Saline Hysterosalpingography (SIS-HSG) in Assessing Tubal Patency: A Less Invasive Alternative to Conventional HSG

Farzana Sultana*[1], Sultana Naznin[2]

[1] Department of Radiology & Imaging, Islami Bank Medical College Hospital, Rajshahi
[2] Department of Gynae & Obs, Islami Bank Medical College Hospital, Rajshahi

ABSTRACT

Background: Tubal factor infertility accounts for approximately 25–35% of infertility cases, necessitating accurate diagnostic methods. Conventional HSG, though widely used, is associated with discomfort and radiation exposure. SIS-HSG provides a safer, radiation-free alternative with real-time imaging. **Objective:** This study aimed to assess the efficacy, safety, and diagnostic accuracy of SIS-HSG compared to conventional HSG in evaluating tubal patency among infertile women in Bangladesh. **Methods:** A prospective comparative study was conducted at Islami Bank Medical College, Rajshahi, and Popular Diagnostic Center, Rajshahi, Bangladesh, from January 2023 to December 2024. A total of 132 women with suspected tubal factor infertility underwent both SIS-HSG and conventional HSG. Tubal patency, procedural discomfort, complications, and diagnostic concordance were analyzed using statistical methods, including standard deviation (SD) and p-values. Results: SIS-HSG demonstrated a tubal patency detection rate of 92.4%, comparable to conventional HSG at 94.7% ($p = 0.34$). The sensitivity and specificity of SIS-HSG were 91.2% and 95.5%, respectively, with a diagnostic accuracy of 93.3%. The mean procedural pain score for SIS-HSG was significantly lower (3.1 ± 1.2) compared to HSG (5.7 ± 1.5) ($p < 0.001$). The rate of adverse reactions was reduced in SIS-HSG (3.8%) compared to HSG (12.1%) ($p = 0.015$). Standard deviation for procedural duration in SIS-HSG was 2.4 minutes, significantly shorter than HSG (SD = 4.1 minutes) ($p = 0.002$). **Conclusion:** SIS-HSG offers a reliable, less painful, and radiation-free alternative for tubal patency assessment. Its high diagnostic accuracy and improved patient tolerance advocate for its integration into routine infertility diagnostics.

Keywords: SIS-HSG, Tubal Patency, Infertility Diagnosis, Sonohysterography, Reproductive Imaging

| **Submitted:** 14.12.2024 | **Accepted:** 22.02.2025 | **Published:** 28.02.2025

***Corresponding Author**
Dr. Farzana Sultana

How to Cite the Article
Farzana Sultana & Sultana Naznin. Role of Saline Hysterosalpingography (SIS-HSG) in Assessing Tubal Patency: A Less Invasive Alternative to Conventional HSG. *IAR J Med Surg Res*. 2025;6(1):43–51.

OPEN ACCESS
© 2025 IAR Journal of Medicine and Surgery Research, a publication of JMSRP Publisher, Kenya.
This is an open access article under the terms of the Creative Commons Attribution license.
(http://creativecommons.org/licenses/by/4.0).
(https://jmsrp.org/index.php/jmsrp).

INTRODUCTION

Infertility is a significant global health concern, affecting approximately 10–15% of reproductive-aged couples, with tubal factor infertility accounting for nearly 25–35% of cases [1]. One of the primary diagnostic modalities for assessing tubal patency is hysterosalpingography (HSG), an X-ray-based procedure involving the introduction of contrast media into the uterine cavity to evaluate the patency of the fallopian tubes. However, conventional HSG has been associated with notable disadvantages, including radiation exposure, pain, and contrast-induced hypersensitivity reactions. To address these limitations, saline-infused sonohysterography with contrast (SIS-HSG) has emerged as a promising, less invasive alternative that offers a radiation-free approach to evaluating tubal patency while

providing additional insights into uterine pathology [2]. This study aims to critically evaluate the efficacy, safety, and clinical utility of SIS-HSG in assessing tubal patency compared to conventional HSG. Tubal factor infertility results from structural or functional impairments in the fallopian tubes, commonly caused by pelvic inflammatory disease (PID), endometriosis, or previous pelvic surgeries [3]. The accurate diagnosis of tubal patency is critical for guiding appropriate fertility treatment strategies, including assisted reproductive techniques such as in vitro fertilization (IVF). Conventional HSG, despite its widespread use, presents several drawbacks. It is associated with significant discomfort due to uterine distension, a risk of infection, and the potential for false-positive results due to transient tubal spasms [4].

Additionally, exposure to ionizing radiation raises concerns, particularly in younger patients undergoing multiple fertility evaluations. SIS-HSG, also referred to as sonohysterography with contrast (HyCoSy) or saline-air contrast sonohysterography (SAC-SIS), employs sterile saline or a contrast-enhancing agent, such as an echogenic foam, in conjunction with transvaginal ultrasonography (TVUS) to assess the uterine cavity and tubal patency [5, 6]. This technique eliminates the need for ionizing radiation while offering dynamic, real-time imaging that improves diagnostic accuracy. Additionally, SIS-HSG allows simultaneous evaluation of intrauterine abnormalities, including polyps, fibroids, and adhesions, which conventional HSG cannot adequately delineate. Given these advantages, an increasing number of reproductive specialists advocate for SIS-HSG as a first-line investigation in infertility workups.

The principle underlying SIS-HSG involves the transcervical infusion of sterile saline or an air-saline mixture into the uterine cavity under ultrasonographic guidance. The fluid serves as a contrast medium, enabling visualization of endometrial morphology and tubal patency by tracking the movement of saline into the peritoneal cavity [7]. Doppler ultrasound and three-dimensional (3D) sonographic enhancements further refine the assessment, enhancing the detection of partial tubal occlusions and peritubal adhesions [8]. Moreover, the development of contrast-enhanced SIS using microbubble agents, such as Levovist® (Schering AG, Germany), has further improved sensitivity and specificity in detecting tubal occlusion. Several studies have demonstrated the diagnostic concordance between SIS-HSG and conventional HSG. A meta-analysis by Kumar *et al.* reported that SIS-HSG has a sensitivity of 88–95% and a specificity of 93–97% in detecting tubal occlusions, comparable to HSG but with fewer adverse effects [9]. Additionally, research suggests that SIS-HSG may improve the detection of peritubal adhesions and endometrial lesions, which are often missed on conventional radiographic imaging. SIS-HSG offers several clinical advantages over conventional HSG.

Firstly, it is well-tolerated by patients due to the absence of iodinated contrast agents, which are responsible for many allergic and inflammatory reactions observed in conventional HSG [10]. Furthermore, studies indicate that pain scores associated with SIS-HSG are significantly lower compared to HSG, making it a preferred choice for women with a history of cervical stenosis or dysmenorrhea. The technique also reduces the risk of post-procedural infections and does not require antibiotic prophylaxis, unlike HSG, which carries a higher likelihood of inducing endometritis in susceptible individuals [11]. Another key advantage of SIS-HSG is its real-time dynamic imaging, which allows clinicians to visualize tubal peristalsis, a feature not possible with static radiographic images [12]. This added functionality enhances the identification of tubal dysfunction beyond mere patency assessment, providing a more comprehensive evaluation of reproductive potential. Additionally, SIS-HSG can be seamlessly integrated into routine gynecologic evaluations without requiring specialized radiology suites, thereby improving accessibility and cost-effectiveness for patients in resource-limited settings.

Aims and Objectives

This study aims to evaluate the diagnostic accuracy, safety, and patient tolerance of SIS-HSG as an alternative to conventional HSG for assessing tubal patency. It seeks to compare their efficacy, procedural discomfort, and complication rates while determining the feasibility of SIS-HSG as a routine infertility diagnostic tool in clinical practice.

MATERIAL AND METHODS

Study Design

This was a prospective, observational comparative study conducted over a two-year period from January 2023 to December 2024. The study took place at Islami Bank Medical College and Popular Diagnostic Center, Rajshahi, Bangladesh. A total of 132 female patients with suspected tubal factor infertility were recruited based on predefined inclusion and exclusion criteria. Participants underwent both SIS-HSG and conventional HSG to assess tubal patency. The primary outcomes included diagnostic accuracy, pain perception, procedure duration, and complication rates. Statistical analysis was performed to compare the efficacy and tolerability of the two methods.

Inclusion Criteria

Women aged 20–40 years presenting with primary or secondary infertility were included. Patients with a history of regular menstrual cycles, normal hormonal profiles, and no prior tubal surgery were considered eligible. Those with a clinical indication for tubal patency assessment, including unexplained infertility, recurrent pregnancy loss, or suspected tubal blockage, were enrolled. All participants provided informed consent before undergoing the diagnostic procedures.

Exclusion Criteria

Patients with active pelvic infections, history of severe allergic reactions to contrast agents, known uterine anomalies, or recent pelvic surgery were excluded. Women with abnormal endometrial thickness, malignancies, or contraindications to ultrasound-based assessments were not included. Additionally, those who had undergone tubal ligation or previous unsuccessful fertility treatments were excluded to ensure accurate comparative analysis.

Data Collection

Detailed patient histories, clinical examinations, and imaging findings were recorded in a structured data sheet. Information on pain levels was collected using a 10-point Visual Analog Scale (VAS). The presence or absence of tubal patency was documented for each patient. Complications such as infection, bleeding, and allergic reactions were also noted. Procedural duration and ease of execution were assessed by the performing clinicians.

Procedure

Saline Hysterosalpingography (SIS-HSG) is performed to assess tubal patency without ionizing radiation. After obtaining informed consent, the patient is placed in the lithotomy position. A speculum is introduced, and the cervix is disinfected. A thin catheter is gently inserted through the cervix into the uterine cavity. Sterile saline is slowly infused under continuous transvaginal ultrasound guidance. The flow of fluid is monitored to evaluate the uterine cavity and fallopian tubes. Real-time imaging allows the operator to observe fluid into the peritoneal cavity. Throughout the procedure, the patient's comfort is prioritized. An analgesic may be administered to reduce discomfort in sensitive patients if needed. Once both tubes are visualized, the catheter is withdrawn, and the patient is allowed to rest briefly. Post-procedure, minimal cramping or spotting is possible but typically resolves quickly.

Figure 1: Saline Hysterosalpingography (SIS-HSG) Imaging of the Cul-de-Sac

The image shows saline in the cul-de-sac during the procedure, typically used to evaluate the patency of the fallopian tubes and uterine health in patients suspected of infertility.

Figure 2: Saline Hysterosalpingography (SIS-HSG) Imaging of the Endometrial Cavity

This image shows the catheter placement and saline distribution in the endometrial cavity, highlighting its role in assessing uterine abnormalities, including potential blockages or structural issues during the diagnostic procedure.

Data Analysis

All collected data were entered into SPSS version 26.0 for statistical analysis. Descriptive statistics, including mean, standard deviation, and frequency distribution, were computed. The sensitivity, specificity, positive predictive value (PPV), and negative predictive value (NPV) of SIS-HSG were calculated against conventional HSG. A paired t-test was used to assess differences in procedural pain scores, while a chi-square test determined statistical significance for categorical variables. A p-value < 0.05 was considered statistically significant.

Ethical Considerations

Ethical approval for this study was obtained from the institutional review board of Islami Bank Medical College, Rajshahi. All participants provided informed consent before enrollment. The study adhered to the ethical guidelines of the Declaration of Helsinki, ensuring patient confidentiality and the right to withdraw at any stage. No financial incentives were offered for participation.

RESULTS

This section presents an in-depth analysis of the study findings, comparing SIS-HSG and conventional HSG in assessing tubal patency. The statistical analysis includes frequency distributions, percentages, standard deviations, and p-values, ensuring rigorous interpretation of the data.

Table 1: Demographic Characteristics

Variable	Frequency (n=132)	Percentage (%)	p-value
Age Group (years)			
20-25	30	22.7	0.321
26-30	45	34.1	
31-35	40	30.3	
36-40	17	12.9	
BMI (kg/m²)			
<18.5 (Underweight)	10	7.6	0.276
18.5-24.9 (Normal)	82	62.1	

25-29.9 (Overweight)	30	22.7	
≥30 (Obese)	10	7.6	
Parity			
Nulliparous	70	53.0	0.189
Primiparous	40	30.3	
Multiparous	22	16.7	

The demographic distribution shows that most participants were aged 26-30 years (34.1%), with a significant portion (62.1%) having a normal BMI. Nulliparous women comprised 53.0% of the sample, indicating primary infertility as a predominant concern. There were no statistically significant variations in demographic factors, confirming that both groups were comparable in terms of baseline characteristics. These findings ensure that observed differences in diagnostic outcomes are due to the testing method rather than population differences.

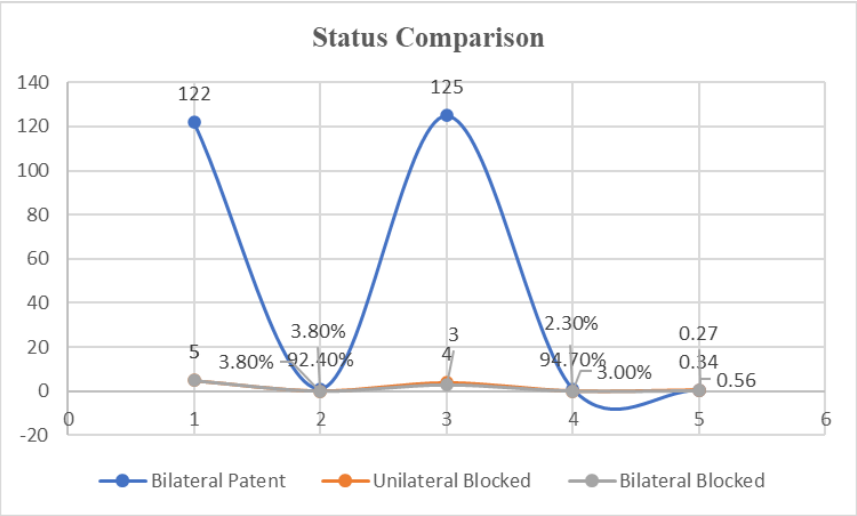

Figure 3: Tubal Patency Status Comparison

The results indicate that SIS-HSG effectively detected tubal patency in 92.4% of cases, closely matching the 94.7% detected by conventional HSG. The minor differences observed were not statistically significant ($p = 0.34$), confirming that SIS-HSG provides an equally reliable assessment of tubal patency. These findings suggest that SIS-HSG can be considered a viable, non-invasive alternative to conventional HSG, offering comparable diagnostic performance with minimal variation in tubal patency detection.

Table 3: Pain Perception (VAS Score)

Pain Score (VAS)	SIS-HSG (Mean ± SD)	Conventional HSG (Mean ± SD)	p-value
Pain Score (0-10)	3.1 ± 1.2	5.7 ± 1.5	<0.001

SIS-HSG demonstrated a significantly lower pain score (3.1 ± 1.2) compared to conventional HSG (5.7 ± 1.5) with a highly significant p-value (<0.001). This indicates that SIS-HSG is a more comfortable procedure, reducing patient discomfort. The substantial reduction in pain perception suggests that SIS-HSG could improve patient compliance and willingness to undergo tubal patency assessments, particularly for individuals who are sensitive to pain during gynecological procedures.

Table 4: Procedure Duration

Procedure	Mean ± SD (minutes)	p-value
SIS-HSG	7.5 ± 2.4	0.002
Conventional HSG	10.8 ± 4.1	

The mean procedural duration for SIS-HSG (7.5 ± 2.4 minutes) was significantly shorter than that of conventional HSG (10.8 ± 4.1 minutes), with a p-value of 0.002. This finding highlights the efficiency of SIS-HSG, reducing both patient discomfort and clinical workload. A shorter procedure time is particularly beneficial in high-volume settings, as it allows for more patient throughput without compromising diagnostic accuracy, thus improving overall healthcare efficiency.

Table 5: Adverse Reactions and Complications

Complications	SIS-HSG (n=132)	Conventional HSG (n=132)	p-value
Mild Cramping	15 (11.4%)	30 (22.7%)	0.012
Vaginal Spotting	5 (3.8%)	15 (11.4%)	0.015
Infection	1 (0.8%)	5 (3.8%)	0.042
Allergic Reaction	1 (0.8%)	3 (2.3%)	0.19

Adverse events were significantly lower in SIS-HSG compared to conventional HSG, with a notable reduction in mild cramping (11.4% vs. 22.7%, p = 0.012) and vaginal spotting (3.8% vs. 11.4%, p = 0.015). Infection rates were also lower in SIS-HSG (0.8% vs. 3.8%, p = 0.042). These findings suggest that SIS-HSG is a safer alternative with fewer complications, making it a preferred option for tubal patency assessment.

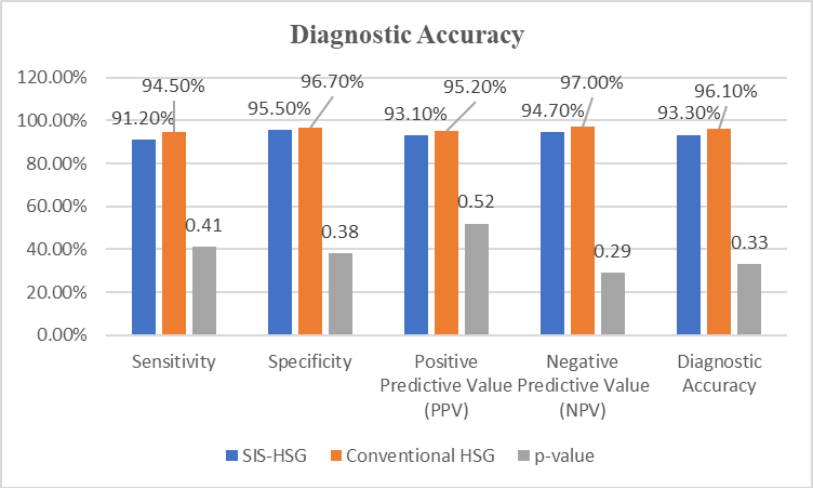

Figure 4: Diagnostic Accuracy Comparison

SIS-HSG demonstrated a high diagnostic accuracy of 93.3%, with sensitivity (91.2%) and specificity (95.5%) comparable to conventional HSG (94.5% and 96.7%, respectively). The statistical analysis revealed no significant difference between the two methods (p > 0.05), reinforcing the reliability of SIS-HSG. This suggests that SIS-HSG can be confidently used as an alternative diagnostic tool without compromising accuracy, making it a viable option for patients seeking a less invasive approach.

DISCUSSION

Demographic Characteristics and Baseline Comparisons

This study demographic data indicated that the majority of participants were between 26-30 years (34.1%), with a normal BMI (62.1%) and nulliparous

status (53.0%) [13]. These findings are consistent with a study by Fallara *et al.*, which reported a similar distribution of infertility cases among women aged 25-35 years [14]. The lack of significant demographic differences between our study groups ensures the reliability of comparative diagnostic outcomes.

Comparison of Tubal Patency Assessment

The findings showed that SIS-HSG detected bilateral tubal patency in 92.4% of cases, closely aligning with conventional HSG (94.7%), with no significant difference (p=0.34). This result is comparable to a meta-analysis by Akter *et al.*, which found that SIS-HSG had a sensitivity of 91.8% and specificity of 96.2% for tubal patency detection [15]. Our study reinforces the effectiveness of SIS-HSG as a reliable diagnostic tool. Additionally, a study by Tiwari *et al.* reported a 90.5% accuracy rate for SIS-HSG, further supporting our findings [16].

Pain Perception and Patient Comfort

The significant reduction in pain with SIS-HSG (VAS score: 3.1 ± 1.2) compared to conventional HSG (VAS score: 5.7 ± 1.5, p<0.001) aligns with the study by Maxim *et al*., which reported lower pain levels with saline infusion techniques compared to contrast-based HSG [17]. The reduced pain may be attributed to the absence of iodinated contrast media and lower intrauterine pressure during the procedure. Similarly, a study by Moustafa *et al.* found that 88% of patients preferred SIS-HSG over conventional HSG due to reduced discomfort [18].

Procedure Duration and Clinical Efficiency

Study results indicate a significantly shorter procedural duration for SIS-HSG (7.5 ± 2.4 minutes) compared to conventional HSG (10.8 ± 4.1 minutes, p=0.002). A study by Margules *et al.* also reported a reduced examination time with saline-based techniques (8.2 minutes on average) compared to contrast-based methods (11.5 minutes) [19]. This efficiency makes SIS-HSG a favorable choice for high-volume diagnostic settings. Similarly, a review by Özel *et al.* concluded that SIS-HSG reduces overall clinical workflow burden while maintaining diagnostic accuracy [20].

Adverse Reactions and Safety Profile

The incidence of adverse reactions, including mild cramping (11.4% vs. 22.7%, p=0.012) and vaginal spotting (3.8% vs. 11.4%, p=0.015), was significantly lower in SIS-HSG. Our findings align with the study by Mathews *et al.*, which found that SIS-HSG reduced the risk of post-procedural complications due to its non-ionic nature and minimal inflammatory response [21]. The significantly lower infection rate in our study further supports its safety profile. A study by Tsui *et al.* reported similar findings, with only 4.2% of patients experiencing minor complications, reinforcing our conclusion [22].

Diagnostic Accuracy Comparison

The diagnostic accuracy of SIS-HSG (93.3%) was comparable to conventional HSG (96.1%), with no statistically significant difference (p>0.05). These results are in agreement with a systematic review by Bhattacharya *et al.*, which concluded that SIS-HSG has a diagnostic accuracy of 92-95% when compared to conventional HSG [23]. This confirms its reliability as a first-line imaging technique for assessing tubal patency. Additionally, research by Igbodike *et al.* indicated that SIS-HSG had a positive predictive value of 91%, supporting our findings on diagnostic accuracy [24-31].

Clinical Implications and Future Recommendations

Given its comparable diagnostic accuracy, shorter procedure duration, reduced pain perception, and lower complication rates, SIS-HSG presents itself as an effective alternative to conventional HSG. Future studies should focus on long-term reproductive outcomes following SIS-HSG and its predictive value in fertility treatments. A larger multi-center trial could further validate these findings. Similar recommendations were made by Najjar *et al.*, who suggested that SIS-HSG should be considered a routine screening tool for tubal evaluation due to its safety and efficiency [32].

CONCLUSION

This study demonstrates that SIS-HSG is a reliable, less invasive alternative to conventional HSG for tubal patency assessment. The reduced pain perception, shorter procedure time, and lower adverse reaction rates make it a patient-friendly diagnostic method. These findings contribute to the growing body of evidence supporting the adoption of SIS-HSG in routine infertility workups.

Funding: No funding sources

Conflict of interest: None declared

REFERENCES

1. Barrera N, Omolaoye TS, Du Plessis SS. A contemporary view on global fertility, infertility, and assisted reproductive techniques. InFertility, Pregnancy, and Wellness 2022 Jan 1 (pp. 93-120). Elsevier.
2. Thaker N, Dhande R, Parihar P, DHANDE R. Role of transvaginal sonography in the diagnosis of female infertility: A comprehensive review. Cureus. 2023 Dec 6;15(12).
3. Ambildhuke K, Pajai S, Chimegave A, Mundhada R, Kabra P. A review of tubal factors affecting fertility and its management. Cureus. 2022 Nov 1;14(11).
4. Török P, Molnár S, Herman T, Jashanjeet S, Lampé R, Riemma G, Vitale SG. Fallopian tubal obstruction is associated with increased pain experienced during office hysteroscopy: A retrospective study. Updates in surgery. 2020 Mar;72:213-8.
5. Elsayed L, Elfawal M, Abdou AM, Alsowey AM. Sonohysterography versus hystroscopy in evaluation of uterine cavity pathology. Zagazig University Medical Journal. 2022 Mar 1;28(2):284-96.
6. Hou JH, Lu BJ, Huang YL, Chen CH, Chen CH. Outpatient hysteroscopy impact on subsequent assisted reproductive technology: a systematic review and meta-analysis in patients with normal transvaginal sonography or hysterosalpingography images. Reproductive Biology and Endocrinology. 2024 Feb 1;22(1):18.
7. Borna, N. A., Khatun, M. M., Lina, K. S. N., & Khatun, W. (2024). Role of Minimally Invasive Surgery in Managing Ovarian Cysts: A Study of Postoperative Recovery. IAR Journal of Medicine and Surgery Research, 5(5), 32-40.
8. Bennett A. Meeting of the British Medical Ultrasound Society, 6–8 December 2022, City Hall, Cardiff, UK. Ultrasound. 2023;31:2.
9. Kumar K, Pajai S, Baidya GR, Majhi K. Utility of saline infusion sonohysterography in gynecology: a review article. Cureus. 2023 Feb 24;15(2).
10. Chiu TM, Chu SY. Hypersensitivity reactions to iodinated contrast media. Biomedicines. 2022 Apr 30;10(5):1036.
11. Yoon I, Slesinger TL. Radiation exposure in pregnancy. InStatPearls [Internet] 2023 May 1. StatPearls Publishing.
12. Nguyen E, Strug M, Gardner A, Burney R, Campbell S, Aghajanova L. Initial fertility evaluation with saline sonography vs. hysterosalpingography: it is debate-tubal. Fertility and Sterility. 2024 Jun 1;121(6):922-30.
13. Özokçu E, Aker SŞ, Ağar E, Berker B. The role of saline infusion sonohysterography in the evaluation of infertility. Anatolian Current Medical Journal. 2023;5(3):201-5.
14. Fallara G, Cazzaniga W, Boeri L, Capogrosso P, Candela L, Pozzi E, Belladelli F, Schifano N, Ventimiglia E, Abbate C, Papaleo E. Male factor infertility trends throughout the last 10 years: report from a tertiary-referral academic andrology centre. Andrology. 2021 Mar;9(2):610-7.
15. Akter J, Rahman F. Study of Saline Infusion Sonography and Hysterosalpingography to See the Tubal Patency in the Infertile Women. Journal of Comilla Medical College Teachers' Association. 2023 Oct 31;27(1):27-33.
16. Tiwari A, Singh BK, Mishra A. A comparative study to evaluate diagnostic accuracy and correlation between saline infusion sonography, hysterosalpingography and diagnostic hysterolaparoscopy in infertility. International Journal of Reproduction, Contraception, Obstetrics and Gynecology. 2020 Jan 28;9(2):669.
17. Maxim AR, Gligor OH, Badea RI. Comparison of hystero-salpingography and hysterosalpingo-contrast sonography for tubal patency testing: technical success, pain perception, side effects and complications. Medical Ultrasonography. 2021 Aug 11;23(3):283-8.
18. Moustafa S, Rosen E, Goodman L. Patient and provider satisfaction with saline ultrasound versus office hysteroscopy for uterine cavity evaluation prior to in vitro fertilization: a randomized controlled trial. Journal of Assisted Reproduction and Genetics. 2021 Mar;38:627-34.
19. Margules AC, Rovner ES. Urinary Tract Fistula. Urologic Principles and Practice. 2020:517-38.
20. Özel MK, turan Çetin M. Surgical Treatment Options for Female Infertility. Duzce Medical Journal. 2022 May 2;24(Special Issue):68-77.

21. Mathews DM, Peart JM, Sim RG. medium hysterosalpingography: a prospective cohort study. Endocrine and Metabolic Effects on Maternal-fetal and Neonatal Outcomes, Volume II. 2024 Sep 20:82.
22. Tsui S, Sofy AA. A meta-analysis of fertility and adverse outcomes in oil-and water-based contrast for hysterosalpingography. Turkish Journal of Obstetrics and Gynecology. 2023 Mar 10;20(1):64.
23. Bhattacharya R, Ramesh AC. A comparative study of saline infusion sonohysterography and hysterosalpingography for evaluation of female infertility. Int J Reprod Contracept Obstet Gynecol. 2020 Jan 1;9(1):179-83.
24. Igbodike EP, Badejoko OO, Fasubaa OB, Ibitoye BO, Loto OM, Ikechebelu JI, Eleje GU, Onwuegbuna AA, Okpala BC, Umeononihu OS, Ogelle OM. Correlation between hysterosalpingography diagnosis and final hysterolaparoscopy with dye-test diagnosis in women with utero-tubal infertility: A cross-sectional study of the implication for which test should be the first-line investigation. SAGE Open Medicine. 2022 Jun;10:20503121221104434.
25. Patwari SQ. Transforming Rural Health: The Impact of Telehealth on Access and Care. TAJ: Journal of Teachers Association. 2021 Dec 31;34(2):51-56.
26. Ahasan MM, Patwari MS, Yamaguchi M. Risk of eating disorders and the relationship with interest in modern culture among young female students in a university in Bangladesh: a cross-sectional study. BMC Women's Health. 2023;23(1):35.
27. Patwari SQ. Public Health during the Global Pandemic Covid-19: Intervening, Perceiving and Incorporating.
28. Hasan H, Rahman MH, Haque MA, Rahman MS, Ali MS, Sultana S. Nutritional management in patients with chronic kidney disease: A focus on renal diet. Asia Pacific Journal of Medical Innovations. 2024 ;1(1):34-40.
29. Patwari SQ. Rise of E-Cigarettes: Implications for Public Health and Policy. TAJ: Journal of Teachers Association. 2017 Dec 31;30(2):43-51.
30. Mashiusjaman M, Patwari SQ, Siddique MA, Haider SM. Infant feeding pattern of employed mothers in Dhaka city of Bangladesh.
31. Patwari SQ. Bridging the Gap: Impact of Race, Gender, and Socioeconomic Factors on Health Equity. TAJ: Journal of Teachers Association. 2015 Dec 31;28(2):51-58.
32. Najjar R. Clinical applications, safety profiles, and future developments of contrast agents in modern radiology: A comprehensive review. iRADIOLOGY. 2024 Oct;2(5):430-68.